


# JOURNAL *of the*

MASSACHUSETTS DENTAL SOCIETY

Summer 2011



The Fine Art  
of Dentistry

# AN "A" FOR THE MDS, BUT AN "F" FOR THE STATE

**W**E OFTEN USE THIS COLUMN AS A BULLY PULPIT FOR THE NEED TO IMPROVE access to care for the poor, the elderly, and children. And while there has been some progress, more often than not there has been frustration and disappointment. A good case in point is the Massachusetts MassHealth Program. We were making great strides in recruiting dentists to become providers and make the financial sacrifice that is part of this commitment. Massachusetts dentists were expressing some satisfaction with the changes that had been made in the program, notably regarding paperwork and the individual control of the number of patients accepted. They were also feeling good about how they were able to provide care to those in need and were finding that this provision of care was well appreciated.

It was starting to work.

Providing care to service the dental needs of those who did not usually have access to care was bound to have concomitant effects. It is a well-known fact that poor dental health can lead to many other systemic issues. A healthy oral condition cuts down on medical and emergency room care, thus providing significant cost savings and much less of a burden on the health care system. Studies have also shown that feeling good about one's smile increases self-confidence. People without oral pain can be much more productive.

Therefore, it was quite disconcerting when Governor Deval Patrick took the easy way out last year with his budget. The short-sighted, convenient step of cutting the adult MassHealth restorative benefits resulted in a far-too-easy target when budgets are developed and cuts are needed. (The FY 2012 budget maintains the same cuts as the FY 2011 budget, so there has been no reversal to the adult benefits.)

The Pew Charitable Trusts recently gave Massachusetts a grade of "A" in providing care for disadvantaged children. In contrast, Pew has been giving poor grades to many of the other states. (In fact, Massachusetts had only a grade of "C" until May 2011.) As one of its solutions to the nationwide problem of access to care, Pew recommended the utilization of independent auxiliary dental care providers to improve access and help rectify the situation. This report and suggested solution should be a strong wake-up call for our profession.

This "A" for Massachusetts does not take into account the inadequate provision of care for underprivileged adults or the elderly. If we do not take the proper steps to protect the quality of care for *all* residents in our state, then we have only ourselves to blame. There are enough dentists in Massachusetts to provide the care that is necessary. Our progress in enrolling dentists to join the MassHealth Program is one example of that.

A better solution is to get our elected officials to think in a more proactive way and to reinstate a program that had the potential to work within the established system by providing quality care to a large segment of our population. Cutting the adult MassHealth restorative benefits for a short-term budget fix is causing a much more profound long-term problem.

If we want to control our own destiny, we have to make the effort to ensure that our government's policies protect the public. Our state legislators really do listen to us, but only if we speak loudly and consistently. ■



*David B. Becker*

*Arthur I. Schwartz*

## JOURNAL OF THE MASSACHUSETTS DENTAL SOCIETY

EDITOR

David B. Becker, DMD, MPH

ASSISTANT EDITOR

Arthur I. Schwartz, DMD

MANAGING EDITOR OF  
PUBLICATIONS AND WEBSITE  
Melissa Carman

MANAGER, GRAPHIC DESIGN  
Jeanne M. Burdette

GRAPHIC DESIGNER  
Shelley Padgett

### EDITORIAL BOARD

Bruce Donoff, DMD, MD

Robert Faiella, DMD

Russell Giordano, DMD

Shepard Goldstein, DMD

Stephen McKenna, DMD

John McManama, DDS

Noshir Mehta, DMD

Charles Millstein, DMD

Philip Millstein, DMD

Maria Papageorge, DMD

Michael Sheff, DMD

Steven Tonelli, DMD

Copyright © 2011 Massachusetts Dental Society  
issn: 0025-4800

The JOURNAL OF THE MASSACHUSETTS DENTAL SOCIETY [usps 284-680] is owned and published quarterly by the Massachusetts Dental Society, Two Willow Street, Suite 200, Southborough, MA 01745-1027. Subscription for nonmembers is \$15 a year in the United States. Periodicals postage paid at Southborough, MA, and additional mailing offices.

Postmaster: Send address changes to: JOURNAL OF THE MASSACHUSETTS DENTAL SOCIETY, Two Willow Street, Suite 200, Southborough, MA 01745.

Contributions: Contact the Communications Department, or visit [www.massdental.org](http://www.massdental.org) for author's guidelines.

Display ad closing dates: February 1, May 1, August 1, November 1. For more information, contact Melissa Carman, Managing Editor, at (800) 342-8747, ext. 260, or email [mcarman@massdental.org](mailto:mcarman@massdental.org).

Member Publication  
American Association  
of Dental Editors



# The 147th MDS House of Delegates



More than 160 Massachusetts Dental Society member delegates, representing all 13 districts, gathered at the 2011 House of Delegates on Friday, May 13, 2011, at the Burlington Marriott. Five resolutions were voted on in total, four of which passed, while one resolution regarding changes to the structure of the Council on Public Affairs was referred back to the council for further review. (For the final resolutions, see [www.massdental.org/hod](http://www.massdental.org/hod).)

The House of Delegates, which was presided over by Speaker of the House Dr. Thomas Torrisi, also welcomed new officers for the 2011–2012 term: Charles Silvius, DDS, a general dentist in Revere and former secretary of the MDS, was sworn in as president; Paula Friedman, DDS, a general dentist in Boston, associate dean at the Boston University Henry M. Goldman School of Dental Medicine, and former chair of the MDS Council on Public Affairs, was named president-elect; Michael Wasserman, DDS, a general dentist in Pittsfield, was sworn in as vice president; and William Dennis, DDS, a general dentist in Shrewsbury and former trustee of the Worcester District, returned to the Board as assistant secretary.

Raymond (Jay) Wise, DDS, a general dentist in Lee, joined the Board as trustee of the Berkshire District. Each governing year, four MDS members are selected to attend Board of Trustees meetings and participate in discussions in a nonvoting capacity as Guest Board Members. This year's slate is: Kathy Alikhani, DMD, an endodontist in Norwell; Margaret Errante, DDS, director of the Boston University Dental Health Center; Nahal Panah, DMD, a general dentist in Melrose; and Frank Schiano, DMD, director of dentistry at Fenway Health in Boston.

Additionally, 66 MDS members were honored at a luncheon for completing 50 years of Society membership (see list at left). To view photos and learn more about Annual Session, visit the House of Delegates page on the MDS website at [www.massdental.org/hod](http://www.massdental.org/hod). ■

## 50-Year Members



- |                             |                                |                            |
|-----------------------------|--------------------------------|----------------------------|
| Eero A. Aijala, DMD         | Nicholas C. Darzenta, DMD      | Sylvio P. Lessa, DMD       |
| Albert L. Bachorowski, DDS  | Vincent DeAngelis, DMD         | David H. Lubin, DMD        |
| Herbert I. Bader, DDS       | George A. Deemys, DMD          | Nicholas Marinakis, DDS    |
| Edward R. Barbagallo, DMD   | Flaviano J. DiFalco, DDS       | Richard E. McVay, DMD      |
| Laurence Barsh, DMD         | Richard P. Dugas, DDS          | William E. Miller, DDS     |
| Bertram M. Beisiegel, DDS   | Frederick J. Feeney, Jr., DMD  | Richard Mooradkhanian, DMD |
| Pallonji M. Bhiladvala, DMD | Howard L. Feldman, DMD         | Robert E. Murray, DMD      |
| Charles F. Bobeck, DMD      | Alfred M. Ferris, DMD          | Clarence J. Myatt, DDS     |
| James N. Bogden, DMD        | Kenneth N. Ferris, DMD         | Eugene B. Myerov, DDS      |
| Roger G. Boisvert, DDS      | Edwin S. Fields III, DMD       | Albert J. Puccia, DDS      |
| Donald F. Booth, DMD        | Frederick J. Giarrusso, DDS    | Thomas W. Quinn, DDS       |
| Arthur J. Bower, DDS        | William J. Girotti, DDS        | Robert G. Rafferty, DMD    |
| Louis A. Bruno, DMD         | Richard K. Grady, DDS          | Raymond J. Roberge, DDS    |
| Douglas A. Bryans, DDS      | Henry R. Groebe, DMD           | Howard Rosenkrantz, DDS    |
| Robert E. Cassidy, DMD      | Paul P. Harasimowicz, Jr., DDS | James H. Sowles, DMD       |
| Edmund F. Cataldo, Jr., DDS | James A. Hazlett, DDS          | Stephen Stone, DMD         |
| Sheldon H. Cohen, DMD       | John R. Horne, Jr., DMD        | Albert C. Sullivan, DMD    |
| James R. Collins, DDS       | Patrick F. Iacovelli, DDS      | Harold W. Tate, Jr., DDS   |
| Paul J. Connelly, DDS       | Samuel A. Ina, DMD             | Dante A. Villani, DDS      |
| Lawrence G. Coulter, DDS    | Joseph G. Kalil, DDS           | Harvey N. Waxman, DMD      |
| Thomas H. Cunningham, DDS   | George M. Klemm, DDS           | J. Robert Wert, DMD        |
| Billy H. Darke, DDS         | Ralph J. Lauretano, DMD        | Alan J. Wright, DMD        |



Eastern Dental Financial Insurance Agency (EDFIA), 200 Friberg Parkway, Suite 2002, Westborough, MA 01581  
Phone: (800) 898-3342 • [www.edic.com/financial-services.html](http://www.edic.com/financial-services.html). Copyright © 2011 Forefield Inc. All rights reserved.

## FIRST MILESTONES MARK NEED FOR FINANCIAL ADVICE

**I**F YOU'RE JUST STARTING OUT, YOU MIGHT not give much thought to working with a financial professional. You may associate the process with retirement—a milestone that seems so far off that more immediate concerns take precedence. The fact is, though, that a financial professional can prove to be a valuable resource to those just starting out. And while there's never a bad time to seek professional advice, early life-changing events make it especially important to take stock of your financial situation.



your bank accounts or keep them separate? In cases where you and your spouse aren't on the same page, a third party can listen to all concerns, identify underlying issues, and help you find common ground. A professional can also work with you to make sure that you're making the most efficient use of employer benefits, including health insurance and qualified retirement plans; that you have adequate life insurance coverage; and that the investments you choose are appropriate for your goals, time frames, and risk tolerance.

### Starting a Career

Taking such a step may seem counterintuitive—when you're starting out, it's often more about anticipating future potential and possibilities than focusing on the present. But this is actually the perfect time to begin building a relationship with a financial professional. It's also the perfect time to establish good financial habits, like building an adequate cash reserve, starting to save on a consistent basis, and establishing a good credit history. You may need help implementing a spending plan (aka "budget") that will help you to meet current financial needs and still enable you to make progress toward your future goals.

It's not all about the future, though. A financial professional can help you get the most out of your paycheck by working with you to maximize the value of tax-advantaged benefits offered by your employer, including employer-provided health coverage or a qualified retirement plan. In addition, you may need help with issues as common as paying back student loans or as complicated as understanding employer stock options.

### Getting Married

You know you need financial help when key words used to solemnize an occasion include "for richer or poorer." There's the immediate financial aspects of a wedding (paying for everything), but, more importantly, there's the long-term financial challenges that come when two individuals combine their finances. Like the ghosts of boyfriends and girlfriends past, you each bring your own financial history, attitudes, and habits—both good and bad—to the union.

A financial professional can help you define your goals as a couple. You'll want to come up with a joint spending plan to help you achieve these goals, and decide on the mechanics of day-to-day money management. For example, will you combine

### Beginning a Family

The period of time following the birth of a child is both exciting and stressful. It's time to completely reevaluate your financial situation, starting with your goals. For example, in addition to saving for your own retirement, it's time to start thinking about saving for your child's college education. Your existing spending plan is likely to be the victim of suddenly decreased income (if there's to be a stay-at-home spouse) or a significant new expenditure (child care). If nothing else, you need to account for the additional ongoing expenses that come with parenthood (e.g., baby formula, food, diapers, and clothing).

With children in the equation, having adequate health insurance, life insurance, and disability income insurance takes on new significance, and you may want to work with someone to evaluate your needs, obtain appropriate coverage, and make sure your beneficiary designations reflect your wishes. It's also time to establish an appropriate estate plan—including a will, health care proxy, and durable power of attorney—or to update an existing estate plan. A financial professional can help walk you through some of the issues involved, and can help you find an attorney if you don't have one already.

### Need for Advice Grows Over Time

If you're like most people, your financial needs will grow more complex over time, and as that happens, your need for financial advice will increase, as well. By starting early, you're able to build on a solid financial foundation. With each life milestone, a financial professional can help you develop a clear picture of your current financial situation, work with you to articulate and prioritize your financial goals and timelines, and recommend strategies and products that are appropriate for your objectives. ■



**GEORGE GONSER**

*Mr. Gonser is CEO of MDSIS—Spring Insurance Group.*

## MANDATED BENEFITS AND HEALTH INSURANCE COSTS

**P**ASSING BY A SCHOOL playground recently, I was struck by the number of children playing in the yard at recess. It got me thinking: How many of these children were created by in vitro fertilization (IVF)? The high cost of health insurance was on my mind, and I wondered what the cost of this mandated benefit and others had on the cost of health insurance in Massachusetts. The results are very interesting.

You probably know people—family, friends, or coworkers—who have had children via IVF. These babies are truly miracles. Go back 30 or so years, and most, if not all, of these babies wouldn't have been born. The benefits are undeniable. However, do you know the cost of IVF? Suffice it to say, it is very expensive. And the cost of these expensive procedures is borne by all health insurance plan subscribers in the Commonwealth of Massachusetts. Why is that, you ask? Because IVF benefits are mandated in Massachusetts. All told, there are more than 26 mandated benefits that are components of each and every person's health insurance plan in our state. These mandated benefits are in the plans whether or not we, as individuals, want or need them.

Is it fair to expect people to pay for something they don't need or want, but that others may need or want? No, but this is par for the course regarding many things in our life. We have all read the statistics—80 percent of insurance policyholders pay for the other 20 percent. Fifty percent of the policyholders pay for 5 percent of the heavy utilizing subscribers. Okay, maybe if the cost of health insurance wasn't so expensive and financially crippling for so many of us, we could—and would—be more willing to absorb these additional costs. The average family plan is now approaching \$20,000 annually per the 2011 Milliman Medical Index. That number, which has more than doubled since 2002, is the same as many people's annual mortgage or rent payments, or more. Business owners and individuals need premium relief, and mandated benefits are in the crosshairs because they have



cost implications for many and help the few, all at a very difficult time for everyone.

Of the 26 mandated benefits in Massachusetts, there are currently six that make up most of the mandated costs: maternity care, home health care, preventive care, infertility services, and, added recently, autism treatment and hearing aids. Conservative estimates put the mandated benefits at 11 to 14 percent of health insurance premium costs. That is a number that is not to be ignored. Should mandated benefits just be stricken altogether? If so, would you see the savings from that estimated 11 to 14 percent?

Probably not. There would still be a certain amount of cost- and benefit-treatment shifting occurring that would cut the overall expense to 3 to 5 percent. Still, 8 to 11 percent of existing premium savings is somewhat enticing.

Some additional food for thought is the current state of health insurance. Health insurance is just that—insurance. It is not a prepayment mechanism for medical services. The current system of health insurance in Massachusetts—and nationally—has skewed the definition of insurance for most consumers.

There are always pros and cons to mandates—for example, the Seat Belt Law. Despite overwhelming evidence supporting seat belts and their ability to save lives, there is a faction that thinks that seat belt utilization should be determined by choice, not mandated by law. The same can be said for the health insurance mandate issue. Some call it too much government intervention; some call it a compassionate directive. Maybe we have hit the tipping point on mandates. Maybe it is time to, at least, curb all future mandates. As the legislature considers a handful of mandates for 2011, keep in mind how they will impact your health insurance premiums.

I have seen the advantages of mandates as well as the disadvantages. One person's gain is another's pain. Welcome to the world of mandated benefits. ■



## VIEWPOINT

**ANTHONY R. SILVESTRI, JR., DMD**

*Dr. Silvestri maintains a private practice in downtown Boston.*

# LINGERING QUESTIONS CONCERNING DELTA DENTAL PREMIER

AS A MASSACHUSETTS DELTA DENTAL Premier participating dentist since 1995, I find the recent 2009 *Decision and Order (Docket G2008-10)*<sup>1</sup> of the Massachusetts Division of Insurance (DOI) eye-opening and disturbing. The DOI, at the insistence of the Massachusetts Dental Society (MDS), investigated the reimbursement methodologies that Dental Service of Massachusetts (aka Delta Dental of Massachusetts) had been employing for nearly two decades. It is important for MDS members to be aware of and understand some findings that emerged from the investigation.

1. The DOI found that Delta Dental's reimbursement methodology of capping maximum allowable fees and subsequently increasing them annually by a Consumer Price Index (CPI) was unreasonable since it did not adequately keep pace with the costs of running a dental practice (see *Docket G2008-10, pages 13–17*). This methodology began in 1990 and continued through 2010.
2. The use of Delta Dental's CPI adjustment was never addressed by the DOI until the recent review that resulted in the 2009 *Decision and Order* (see *Docket G2008-10, page 13* and footnote 26).
3. The DOI reasoned that dentists who signed contracts to become Premier providers as far back as 1990 may have been confused about Delta Dental's fee capping/CPI upgrade policy, since Delta Dental provided little information to dentists and written literature concentrated on maximum allowable fees being set in the 90th percentile of Delta Dental network providers (see *Docket 2008-10, page 15*).

Because Delta Dental is a *not-for-profit* company with tax-advantaged privileges granted to it by the Commonwealth of Massachusetts, the DOI has the responsibility to oversee the fairness of certain insurance business practices, such as reimbursement methodologies. It is disheartening to discover, 16 years after signing my contract, that the DOI had never approved of critical aspects of Delta Dental fee upgrading practices and that those practices were, indeed, unreasonable all along. Therefore, over the past two decades, dentists like me have signed contracts with Delta Dental with neither the DOI nor the dentists themselves having knowledge of how fees were being



determined. How many dentists might not have signed contracts with Delta Dental had the actual fee methodology been openly disclosed to them? Who is responsible for payment shortfalls that might have occurred as a result of the unreasonable fee upgrade methodology Delta Dental used?

Delta Dental was asked to give testimony to the DOI in order for the DOI to understand the magnitude of dollars held back due to its fee capping/CPI upgrade methodology (see *Docket G2008-10, Exhibit C*).<sup>2</sup> Delta Den-

tal provided the DOI with an affidavit showing that payments for submitted claims were reduced by more than \$80 million in 2008 alone as a result of the fee capping methodology. How many of these dollars might Premier providers have received if Delta Dental had not used an unreasonable fee upgrade methodology, and how big might the number be if multiplied over 20 years?

In a letter to the DOI for the recent hearing, Delta Dental estimated that since 1990, the CPI it used to upgrade capped fees averaged 2.9 percent per year, while the actual real dentist costs to do business (dental CPI) was rising at an average rate of 4.9 percent.<sup>3</sup> The DOI rightfully concluded in its 2009 *Decision and Order* that using such a fee upgrade methodology would result in fee profiles diverging further and further away from real-world office fees over time (see *Docket G2008-10, page 14*). The 2 percent rate difference compounding annually for 20 years has a significant negative effect on fee profiles. What might Delta Dental fee profiles look like had a reasonable methodology been applied for all those years?

When I signed my contract with Delta Dental, its reimbursements for procedures were relatively close to what every other patient in my office was paying for the same services. I believed maximum allowable fees were being set in the 90th percentile of all dentists within the network. I felt reassured knowing that important contractual information like reimbursement methodologies had been reviewed and approved by the Massachusetts DOI for fairness. It is an understatement to say that 16 years after signing my contract, I feel betrayed.

At the time of the 2009 *Decision and Order*, 293 of the total 294 procedure codes had maximum allowable fee profiles set not in the 90th percentile, but rather, by an unreasonable fee capping/CPI methodology (see *Docket G2008-10, page 15*) that had not been disclosed to dentists or the DOI. The Premier con-

tract reads, "Delta Dental Plan payments to participating dentists are on a variety of bases of compensation, which have been approved by the Board of Directors and the Commissioner of Insurance, and as delimited by the Rules and Regulations." How did the DOI overlook Delta Dental's unreasonable CPI adjustment for 20 years, and how did this serious breach occur?

When Delta Dental's new 2011 regionally based fee schedule first arrived in my office, I was initially excited to see it. I naively hoped for a methodology that might reconcile 20 years of unfair CPI adjustments. To my surprise, reimbursements for many procedures were significantly *reduced*. Delta Dental's own estimates project that my office income will significantly *decrease* with the implementation of the new schedule.<sup>4</sup> Delta Dental had its birth in partnership with organized dentistry. How many dentists still feel a partnership exists between Delta Dental and Massachusetts dentists? ■

### References

1. Division of Insurance. Decision and order regarding the fee methodology of the Delta Dental Premier Plan, Docket No. G2008-10. Commonwealth of Massachusetts, Office of Consumer Affairs and Business Regulation. 2009 Apr 14.
2. Division of Insurance. Explanation of the supporting calculations for Delta Dental's response to question #12, affidavit of Fay Donohue, decision and order regarding the fee methodology of the Delta Dental Premier Plan, Exhibit C, Docket No. G2008-10. Commonwealth of Massachusetts, Office of Consumer Affairs and Business Regulation. 2009 Apr 14.
3. Division of Insurance. Letter sent from Dental Service of Massachusetts to Kevin Beagan, Deputy Commissioner, Bureau of Managed Care, Division of Insurance, Re: Dental Service of Massachusetts, Inc. d/b/a Delta Dental of Massachusetts—New Fee Methodology. 2010 Jun 7.
4. Delta Dental of Massachusetts. Cohen, Silvestri & Hammer/2011 fee analysis. 2010 Sep 3.

*Welcome all for a...*

## FUN FALL WEEKEND ON CAPE COD

FRIDAY, SEPTEMBER 23, 2011 (lecture)

SATURDAY, SEPTEMBER 24, 2011 (hands-on)

## MA/AGD 6th ANNUAL CAPE COD

J. MURRAY GAVEL  
COURSE AND MEETING

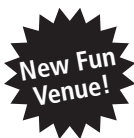## IMPLANTS for the GP Planning to Placement

Speaker

Dr. Michael Pruett, Medical College of Georgia

CAPE CODDER Resort and Spa  
1225 Iyannough Road, Hyannis, MA 02601  
(888) 297-2200 or (508) 771-3000

AGD members \$475, non-AGD members \$575,  
students and staff \$135



For more information or to sign up for this course  
send name, address and phone number to:

MA Academy of General Dentistry  
Cape Cod Course, c/o Dr. Matt Healey,  
PO Box 461, Billerica, MA 01821



*A new name and a new look...  
but the same great service.*



### Implant Systems

- All implant systems
- Authorized NobelGuide™ Dental Laboratory
- Radiographic and surgical guides
- Distributor for 3i®, AstraTech, Nobel Biocare™ and Straumann implant components

### Removable Prosthetics

- Ivoclar® injected complete dentures
- Ticonium cast partial frameworks
- Night guards – hard/soft laminated
- Denture relines and laser-welded repairs

### Conventional Services

- Full-mouth reconstruction
- Precision attachment combination restorations
- Maryland and Monodont bridges
- Temporaries – heat cured – cast reinforced
- Full gold crowns, inlays and onlays

### Ceramic Systems

- CAD/CAM technologies
- Major "all-ceramic systems"
- Diagnostic waxups for full arch treatment planning

**Cresco™ Precision  
Implant Frameworks**  
"Precision Laboratory"

**Call today for your free "new doctor" kit  
781.828.2808**

Quality ■ Service ■ Expertise



76 Pond St. ■ P.O. Box 355 ■ Sharon, MA 02067  
781.828.2808 ■ www.dickermantdental.com



Photograph © August 2011 Museum of Fine Arts, Boston

## Dentistry at the Museum of Fine Arts, Boston: An Artist Paints an Itinerant Dentist's Family

**H. MARTIN DERANIAN, DDS, FACD, FICD**

*Dr. Deranian is a life member of the Massachusetts Dental Society, a dental historian, and a fellow of the American College of Dentists and the International College of Dentists. In 1993, he established the H. Martin Deranian Dental Museum at the Tufts University School of Dentistry. He maintains a general dental practice in Worcester.*

The new Art of the Americas Wing, which opened at the Museum of Fine Arts, Boston, on November 20, 2010, occupies 133,491 square feet and contains 53 new galleries allowing for more than 5,000 works from the museum's collection to be on view.<sup>1</sup> In the wing's gallery devoted to folk art, there hangs a large-scale canvas painting approximately 7 feet by 8 feet:

*Erastus Salisbury Field, American, 1805–1900  
Joseph Moore and His Family, about 1839, oil on canvas  
M. and M. Karolik Collection of American Paintings*

The child at the extreme left of the painting is holding two dental instruments, which, in all probability, came from Joseph Moore's itinerant dental chest. Moore lived in central Massachusetts, in the Ware area, and he was a hatmaker in wintertime and an itinerant dentist in summertime, when the roads were passable. In those days, most dental practitioners were itinerant, since only a large city could support a dentist. It was not

*Journal of the Massachusetts Dental Society*

unusual for dentists to combine dentistry with other trades.

In the painting, Moore and his wife, Almira, are surrounded by their two sons, at right, and their recently orphaned niece and nephew, the children of Almira's sister, at left.<sup>2</sup>

Joseph Moore had little to draw upon in his dental chest or to offer his patients in theory or practice. There was no anesthesia. It was not until 1844 when Dr. Horace Wells offered nitrous oxide or until 1846 when Dr. William T. G. Morton presented ether. Drills were operated by hand; the dental foot engine did not appear until 1872. Moore had porcelain dentures and teeth, which he called "mineral incorruptible teeth." Rubber vulcanite for dentures was not patented until 1844. He used crude silver-mercury amalgam for fillings, as well as lead and gutta-percha.<sup>3</sup>

With handbills and broadsides, Moore would announce his arrival in a community. "He has taken a room for a few days," the advertising would read, and "will attend to all operations" at the patients' residences.

The first dental school in the world had not been established as yet; that occurred in Baltimore in 1840. Moore's training had been as a preceptor, spending a few weeks or more with an established practitioner. There were no regulations, no licenses, and no educational standards.<sup>4</sup> It took the next 20 years for these issues to be formally addressed in 1859 when the American Dental Association was formed.<sup>5</sup>

In Moore's parlor, his neighbor, Erastus Salisbury Field, an itinerant artist, painted what has been called by Lipman and Armstrong "a landmark of 19th century painting" and by Ward et al. as "the largest and most complex [Field] ever painted."<sup>6</sup> Whether Field was Moore's dental patient remains unknown, but they shared more than a passing acquaintance and possibly extended family kinship.

Erastus Salisbury Field was born in 1805 in Leverett, Massachusetts, and was essentially self-taught, except for a three-month period of training in New York with Samuel F. B. Morse, the developer of the electric telegraph and himself a painter of note.

Field is remembered as a "folk artist" during his earlier years (until 1841) and as an itinerant portraitist who, for a decade (1832–1842), successfully traveled the byways of Massachusetts and Connecticut from his home in Palmer. Critics have observed that Field's work has a tendency toward flat, stylized forms, and

*Vol. 60/No. 2 Summer 2011*

have pointed out his problems with foreshortening and his focus on the details of costume and decoration.<sup>7</sup> The six figures in the painting of Joseph Moore's family "are set on an exuberant patterned carpet with a mustard ground and a design in Indian red and dull green."<sup>8</sup>

"Field combines careful attention to detail," wrote Ward et al., "[scrupulously recording Moore's birthmark and the ornate pattern of Mrs. Moore's collar] with attractive eccentricities of composition and drawing. The figures and the features of the room are stringently balanced. However, Field's perspective is haphazard; the mirror's shadow recedes in the wrong direction, and the patterned carpet is not foreshortened and so appears to run uphill. And the children look like little elves, with pointy ears and stubby fingers."<sup>2</sup>

Following the portrait of Joseph Moore and his family, the direction of Field's art turned more toward classical mythology and biblical history, and he is noted for his grandiose "Historical Monuments of the American Republic."<sup>9</sup> To this day, Field's painting of the Moore family remains as a landmark of 19th-century folk art. ■

### References

1. Elliot BD. The new Art of the Americas Wing at the Museum of Fine Arts, Boston. *Antiques and Fine Art*. 2010;10(5):158.
2. Ward GW (editor). *American folk*. Boston (MA): MFA Publications; 2001. p. 22.
3. Ring ME. *Dentistry, an illustrated history*. New York (NY): Harry N. Abrams Publishers; 1895.
4. Tymeson MM. *But one lamp*. Centennial Booklet, Massachusetts Dental Society. Worcester (MA): Commonwealth Press; 1964. p. 15.
5. American Dental Association. *150 years of the American Dental Association, a pictorial history, 1859-2009*. Virginia Beach (VA): The Donning Company Publishers; 2010.
6. Lipman J (editor), Whitney Museum of American Art, Armstrong T. *American folk painters of three centuries*. New York (NY): Hudson Hills Press; 1980. p. 77.
7. Falk PH (editor). *Who was who in American art, 1564-1975, 400 years of artists in America*. Madison (CT): Sound View Press; 1999. Vol. 1. p. 1115.
8. Black M. *Erastus Salisbury Field: 1805-1900*. Springfield (MA): Museum of Fine Arts; 1984. p. 29.
9. Groce GC, Wallace DH. *The New York Historical Society's dictionary of artists in America, 1564-1860*. New Haven (CT): Yale University Press; 1957. p. 224-225.

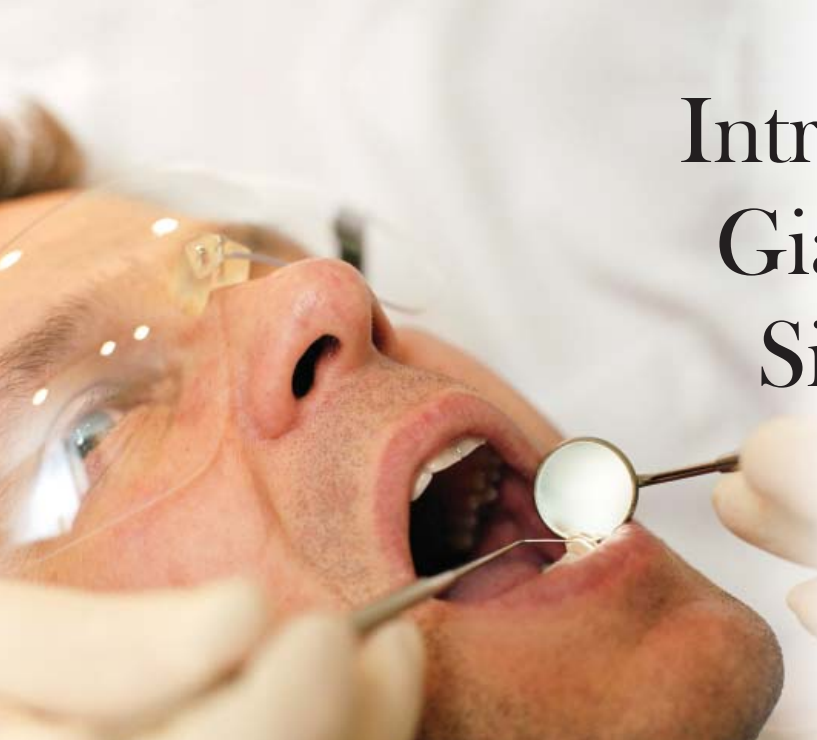### Art Object

Photograph © August 2011 Museum of Fine Arts, Boston



Photograph © August 2011 Museum of Fine Arts, Boston





# Intraoral Removal of a Giant Submandibular Sialolith Obstructing Wharton's Duct: A Case Report

**DAVID COTTRELL, DMD**  
**MICHAEL COURTNEY, MA**  
**ISHWAR BHATIA, MDS**  
**GEORGE GALLAGHER, DMD**  
**DEVAKI SUNDARARAJAN, BDS**

*Dr. Cottrell is a clinical professor and director of residency training, Mr. Courtney is a fourth-year dental student, and Dr. Bhatia is a clinical professor in the department of oral and maxillofacial surgery, and Dr. Gallagher is a clinical professor and department chair and Dr. Sundararajan is a clinical professor in the department of oral and maxillofacial pathology at the Boston University Henry M. Goldman School of Dental Medicine.*

## Abstract

Sialolithiasis is one of the most common pathologies of the submandibular gland; sialoliths account for about 80 percent of all salivary duct calculi. This report presents the unusual case of a large asymptomatic sialolith of the submandibular duct, initially diagnosed as a possible tumor. The giant sialolith was removed via an intraoral approach under local anesthesia. The etiology, pathogenesis, and management of such giant sialoliths are discussed.

## Introduction

**O**bststructive salivary gland disease is one of the most common pathologies affecting the salivary glands and ducts, and is a major cause of salivary gland dysfunction.<sup>1</sup> Sialolithiasis accounts for more than 50 percent of salivary gland disease and is estimated to affect 12 in 1,000 persons in the adult population every year.<sup>2</sup> Most salivary stones (80 to 95 percent) occur in the submandibular gland or its duct, whereas 5 to 20 percent are found within the parotid gland.<sup>2-4</sup> The sublingual gland and minor salivary glands are rarely (1 to 2 percent) affected.<sup>2</sup> The size of salivary calculi may vary from less than 1 mm to a few centimeters in size, with most calculi being less than 10 mm in size. However, giant sialoliths (>15 mm) in the submandibular duct have rarely been reported.<sup>5</sup>

Sialolithiasis typically presents as a painful swelling of the affected gland during mealtimes, and while diagnosis is not commonly difficult, the condition can often be asymptomatic or associated with infectious sialadenitis. Stone formation can partially or completely obstruct glands and their ductal pathways, leading to infection and pain. However, most salivary stones are asymptomatic. Sialoliths do not commonly cause full obstruction of salivary flow, but in such cases, saliva from the remaining salivary gland provides sufficient compensation for digestive processes. Symptoms tend to occur when salivary stones move and cause complete obstruction. In these circumstances (e.g., during meals), the gland can inflate with obstructed saliva, causing swelling and discomfort.<sup>6</sup>

Sialoliths form as a result of precipitation of calcium salts and mineralization of debris that has accumulated in the duct lumen.<sup>7</sup> Radiopacity is not a feature in 40 percent of parotid and 20 percent of submandibular stones, and therefore other imaging techniques, including computed tomography (CT), may be required for stone identification and diagnosis.<sup>7,8</sup>

Current therapeutic approaches have focused on gland-preserving surgery using minimally invasive techniques.<sup>9,10</sup> An important principle that supports the move away from sialoadenectomy is that secretory function can recover after removal of the obstruction.<sup>9</sup>

## Methods

The present study was performed on a patient with informed consent. Sialolithectomy was the treatment of choice via an intraoral approach under local anesthesia. The clinical characteristics, pre- and postoperative data, and outcomes were documented accordingly.

## Case Report

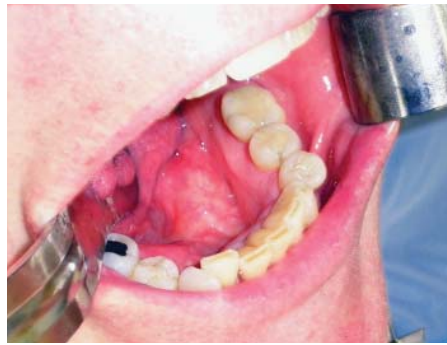A 75-year-old male was referred to our clinic for evaluation of a large hardened mass in the anterior left sublingual region. There were no symptoms of pain, infection, or discomfort associated with the mass; however, it was discovered during regular comprehensive oral care by his general dentist and was thought to possibly be a tumor. An occlusal radiograph and two panoramic radiographs were used for diagnosis.

Upon extraoral examination, no submandibular swelling could be detected. Extraoral palpation did not reveal any masses, asymmetries, tenderness, or lymph node enlargement. Upon intraoral examination, diffuse swelling could be palpated in the left sublingual region near the floor of the mouth. (See Figure 1.) The mass was hard and there were no signs of ulceration, fistula, or infection. The mass was freely movable, was not fixed to any tissues, and could be visualized immediately under the sublingual tissues. Upon palpation of the left submandibular gland and compression of the floor of the mouth, there was an absence of salivary flow from the left Wharton's duct orifice.

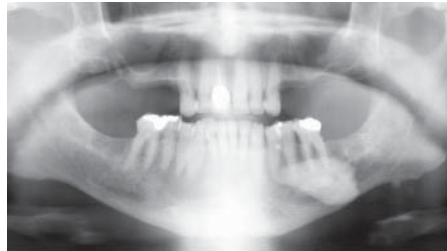
The patient reported a history of hypertension and type II diabetes, and said that he took one adult aspirin per day. The aspirin was discontinued two days prior to surgery, along with metformin. He also reported alcohol consumption and smoking on a daily basis, and had no known drug allergies. Vitals and blood sugar levels taken prior to surgery, as well as postoperatively, were found to be normal.

Panoramic radiograph examination revealed a large radiopaque mass, ovoid in shape with concentric ring formation. (See Figure 2.) An occlusal radiograph revealed similar findings. (See Figure 3.) The stone was approximately 3 cm × 2 cm × 2 cm in dimension. (See Figure 4.) Posteriorly, several smaller calcifications were noted, measuring approximately 4 mm and 3 mm in diameter.

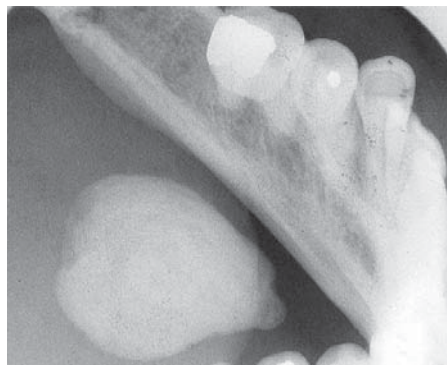
A CT scan revealed similar diagnostic findings of a left sublingual mass consistent with a large salivary gland stone. The smaller additional calcifications were also illustrated in the scan, approximating 2 mm to 3 mm in diameter, located well posterior to the large stone. The smaller calcifications were located in the region of what appeared to be an at-



**Figure 1. Preoperative clinical features of gingival mucosa overlying sialolith in submandibular gland duct are shown, presenting as large, firm mass.**



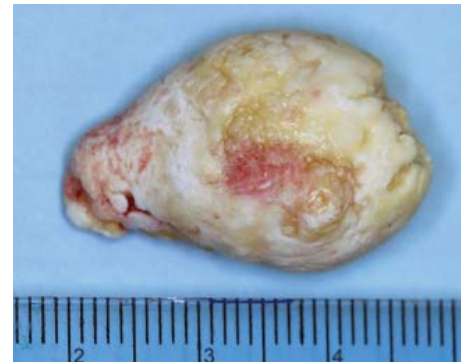**Figure 2. Preoperative panoramic radiograph shows large sialolith in left submandibular region posterior to the body of the mandible.**



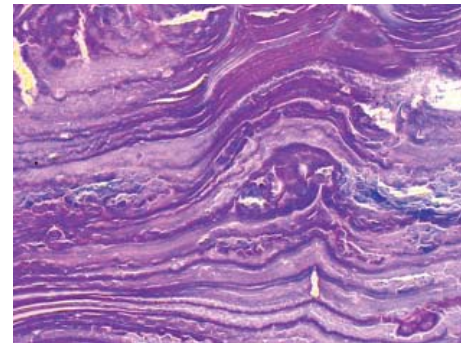
**Figure 3. Preoperative occlusal view radiograph illustrates the superior aspect of the submandibular duct stone.**

rophied left submandibular gland. It was determined that the smaller stones would not be excised due to their posterior location near the hilus and close proximity to the posterior border of the mylohyoid muscle. The parotid glands were symmetric and unremarkable. The right side was within normal limits; neither side revealed inflammation, ductal dilation, fluid collection, or inflammatory change.

Following administration of local anesthesia, a 1.5 cm incision was made just lateral and superior to the tissue surrounding the stone. No bleeding was encountered. A hemostat was used to expose the superior aspect of the stone. The large stone was then removed from the duct with extraoral finger pressure from



**Figure 4. Large sialolith measures approximately 3 cm × 2 cm × 2 cm.**



**Figure 5. Histological sections of the stone reveal layers of calcification.**

underneath the submandibular space, in addition to a pulling force with the hemostat. The wound was sutured open with 3-0 chromic gut sutures to pull open the lateral aspect of the flap medially, and one horizontal mattress suture was placed around the first molar tooth to hold the lateral aspect of the flap laterally and maintain an open wound site to prevent scarring and future closure of the site. Successful removal of the sialolith was confirmed with a panoramic radiograph. Postoperative instructions were provided to the patient. Tylenol was the only pain relief medication taken to alleviate symptoms due to a history of problems with stronger pain medications.

Histological appearance of the salivary stone was a calcified deposit with fibrous tissue. Decalcified sections revealed a mass exhibiting concentric laminations along with amorphous debris. (See Figure 5.) No evidence of malignancy was observed in the sections studied.

At the follow-up appointment two weeks postoperatively, there was no swelling of the submandibular gland or other intraoral areas. There was no noted redness, erythema, or sign of infection, and only mild tenderness to palpation was found. The surgical area was

firm with a scarlike texture, and there continued to be no saliva milked from the left Wharton's duct. The patient reported experiencing postoperative pain and discomfort that he described as "a toothache that would not subside" for the first 10 days. At two weeks postoperative, the patient noted a minor decrease in sensation on the left tip of his tongue that he likened to "a hot coffee burn," suggesting minor paresthesia and dyesthesia.

Two months postoperatively, there was continuous sensation in his tongue. There was no pain associated with his tongue and the patient had not noticed any changes to saliva production.

## Discussion

The exact etiology and pathogenesis of salivary calculi is a largely unknown phenomenon; development may arise from the deposition of calcium salts around a nidus of debris within the duct system.<sup>11-13</sup> Salivary stagnation due to inadequate drainage, bacterial infection, and epithelial injury along the duct may also play a role in the formation of stones.

In contrast to the small-sized calculi, 20 to 30 percent of which are radiolucent, giant sialoliths are commonly identified on panoramic radiographs as a radiopaque mass localized in the submandibular region.<sup>2</sup> Standard intraoral radiographs are not always sensitive enough to identify sialoliths in the early stages of calcification, and the need for more powerful visualization techniques, including computed tomography, is frequently required.

In this case, prophylactic removal of the sialolith was performed to prevent further scarring and gland dysfunction, as well as to prevent possible retrograde infection, particularly given the patient's history of diabetes and advanced age. Conditions of de-

creased salivary flow present the possibilities of an ascending or retrograde bacterial infection of the salivary gland due to reverse flow of bacteria-laden oral fluids.<sup>14</sup>

Removal of stones through an intraoral approach is recommended whenever stones can be palpated intraorally.<sup>15,16</sup> Wharton's duct should be isolated first, followed by a longitudinal incision into the duct over the stone when performing stone removal from the duct. When a direct cut-down method is applied, the initial incision is taken directly to the depth of the stone without primary isolation of the duct.<sup>17</sup>

Larger sialoliths tend to result in fibrotic scarring and poor prognosis of salivary function due to long-standing sialadenitis. No major complications were encountered during the surgery; however, no improvement in saliva production was detected in the left submandibular gland after removal of this large stone at the two-month postoperative evaluation.

## Conclusion

Management of large sialoliths remains a diagnostic and therapeutic challenge to the clinician. The choice of surgical treatment and the preservation of the submandibular gland require careful consideration when dealing with larger sialoliths. In this case, sialolithectomy was the treatment of choice due to the location of the stone within Wharton's duct as opposed to calcifications within the gland. ■

## References

- Liao G, Su Y, et al. Sialoendoscopic secondary intervention after failure of open sialolithectomy. *J Oral Maxillofac Surg.* 2010; 68(2):313-318.
- Biddle RJ, Arora S. Giant sialolith of the submandibular salivary gland. *Radiology Case Reports.* [Online] 2007;2:101.
- Levy DM, ReMine WH, Devine KD. Salivary gland calculi. Pain, swelling associated with eating. *JAMA.* 1962;181(3):1115-1119.
- Bodner L. Salivary gland calculi: diagnostic imaging and surgical management. *Compendium.* 1993;14(5):572, 574-576.
- Gehani E, Krishnan B, et al. Submandibular giant sialoliths: report of two cases and review of the literature. *Ear Nose Throat J.* 2010;89(6):E1-4.
- Zhang L, Escudier M et al. Long-term outcome after intraoral removal of large submandibular gland calculi. *Laryngoscope.* 2010;120(5):964-966.
- Cawson R, Odell E. Cawson's neoplastic and non-neoplastic diseases of the salivary glands. *Essentials of Oral Path and Oral Med.* Philadelphia (PA): Churchill Livingstone; 1998. p. 239-240.
- Lee L, Wong Y. Pathogenesis and diverse histologic findings of sialolithiasis in minor salivary glands. *J Oral Maxillofac Surg.* 2010;68(2):465-470.
- Iro H, Zenk J, Escudier M, et al. Outcome of minimally invasive management of salivary calculi in 4,691 patients. *Laryngoscope.* 2009;119(2):263-268.
- Walvekar R, Bomeli S, et al. Combined approach technique for the management of large salivary stones. *Laryngoscope.* 2009;119(6):1125-1129.
- Escudier MP. Aetiology and epidemiology of salivary calculi. In: *Controversies in salivary gland disease.* McGurk M, Renahan A, editors. Oxford (UK): Oxford University Press; 2001. p. 249-255.
- McGurk M, Escudier M, Brown JE. Modern management of salivary calculi. *Br J Surg.* 2005;92(1):107-112.
- Neville BW, Damm DD, Allen CM, et al. *Oral and maxillofacial pathology.* Philadelphia (PA): W.B. Saunders; 1995. p. 326-327.
- Schlossberg D. *Clinical infectious disease.* New York (NY): Cambridge University Press; 2008. p. 67.
- Rai M, Burman R. Giant submandibular sialolith of remarkable size in the comma area of Wharton's duct: a case report. *J Oral Maxillofac Surg.* 2009; 67(6):1329-1332.
- Leung AK, Choi MC, Wagner GA. Multiple sialoliths and a sialolith of unusual size in the submandibular duct: a case report. *Oral Surg Oral Med Oral Pathol Oral Radiol Endod.* 1999;87(3):331-333.
- Baurmash H. Submandibular salivary stones: current management modalities. *J Oral Maxillofac Surg.* 2004;62(3):369-378.

**Take this Summer  
(and all future Summers) off!**

**PARAGON**  
DENTAL PRACTICE TRANSITIONS

Many professionals believe that the value of your dental practice may be at an **ALL TIME HIGH.**

Take some time to talk to your PARAGON practice transition consultant and find out what the current market value is for your dental practice.

Consider selling it at its peak, maybe even before the nice weather starts.  
After all, how many summers do we get?

**Sign up for our free newsletter at [paragon.us.com](http://paragon.us.com).  
Contact us at 866.898.1867 or [info@paragon.us.com](mailto:info@paragon.us.com).**

# Xylitol and Caries Prevention

JANAINA HANSON

LINDA CAMPBELL

*Ms. Hanson and Ms. Campbell are students in the dental hygiene program at Cape Cod Community College. This article originally appeared as a student presentation at Yankee Dental Congress 36 in January 2011.*



## Background

Xylitol is a sweet crystalline carbohydrate that has been known to science for nearly 100 years. The name relates to the word “xylose” (wood sugar) from which xylitol was first made, and which is, in turn, derived from the particular structure (xylene) of hardwood from which xylose can be obtained. Later studies showed that xylitol occurs freely in fruits and other plant parts, and in virtually all products made of fruits. Xylitol is also present in human metabolism as a normal metabolic intermediate (in the glucuronate-xylulose cycle). In chemical nomenclature, xylitol is classified similarly to sorbitol and maltitol (i.e., as a sugar alcohol or a polyol). The theoretical calorie value of xylitol is the same as with other dietary carbohydrates (i.e., about 4 kcal/g). In practice, however, the caloric utilization of xylitol by the human body may be lower owing to the slow and incomplete absorption of xylitol, especially if larger quantities are consumed. On food labels, the U.S. Food and Drug Administration (FDA) allows a reduced calorie claim for xylitol (2.3 kcal/g). Xylitol is currently manufactured from various xylan-rich plant materials; xylan is the natural polysaccharide that consists of xylose units. Although xylitol occurs freely in nature, it is more economical to use certain plant parts as starting material, such as birchwood, corn residues, straw, seed hulls, and nut shells.

Clinical studies carried out during the past 25 years strongly indicate that xylitol can decisively improve caries prevention. The purpose of this article is to briefly review the most important clinical studies carried out on xylitol, and to discuss practical aspects of the usage of xylitol in caries limitation. The aim is to emphasize the strong position the xylitol-based prevention concept has attained, and the endorsements this strategy has received within the public health sector.

It can be said that Americans have acquired a taste for sweets. Since World War I, the public’s sugar consumption has continued to creep upward. It now exceeds 120 pounds (54.5 kg) per person each year.<sup>2</sup> Highlighting the negative health concerns from excessive sugar consumption, such as diabetes, has emerged as a priority among many public health initiatives. In some cases, communities have attempted to restrict the sale of soda and sugary beverages in public schools. Dentists and dental hygienists can help bolster public awareness of the benefits of replacing sugar with a regimen of non-sugar sweeteners for improved oral and digestive health.

Several of the studies reviewed for this article include special features that may be important to consider in clinical practice and in disseminating the necessary information to patients. Some of these aspects are: long-term effects of xylitol, hyposalivation, and dry mouth syndrome; stabilization of rampant caries; prevention of root surface caries; the mother-child relationship from the cariologic point of view; and implementation of

## Introduction

**M**aximized prevention of dental caries presumes simultaneous and continuous exploitation of several strategies. Fluoride-based procedures are the cornerstone of successful prevention. Rigorous, long-term restriction of cariogenic sugars undoubtedly also results in significant caries reduction. However, considering people’s preferences for sweet food items, restricting cariogenic sugars without offering alternatives is impractical.<sup>1</sup> Therefore, in clinically difficult situations such as rampant caries, profoundly caries-susceptible tooth structure, poor diet, hyposalivation, and amelogenesis imperfecta, the use of noncariogenic sugar substitutes should automatically be considered.

school prevention programs. It is also important to emphasize the advantage that patients will gain from systematic usage of xylitol-containing saliva stimulants. Even in the case of total absence of caries, xylitol is still dentally safer than fermentable sugars, such as regular table sugar (sucrose).

### Xylitol Beyond Caries Prevention

Kontio et al. reported that “the usage of xylitol chewing gum or syrup by young daycare center subjects was associated with reduced rate of acute otitis media [middle ear infections] and with a lowered nasopharyngeal carriage rate of pneumococci.”<sup>3,4</sup> Another important application of xylitol is its use as a source of energy in parenteral nutrition (infusion therapy).<sup>5</sup> Peldyak and Makinen reported that German physicians have used xylitol in substantial quantities for intravenous feeding of patients with impaired glucose tolerance, and when administered in this fashion, xylitol was found to have a strong anticatabolic muscle-sparing effect.<sup>6</sup>

Dental hygienists mainly focus on basic prevention measures, which include professional cleaning and oral hygiene instructions, and the promotion of sugar-restrictive strategies often fail because the benefits and solutions are not always clearly understood by the public at large. The fundamental goal of providing good oral hygiene instruction is to encourage better practices; a sound understanding of the topic supported with this evidence produces convincing instruction.

### Impact of Xylitol Gum on Maternal Transmission of *Mutans Streptococci*

Research reveals that xylitol can reduce mother-child transmission of the bacterial disease that causes caries: *mutans streptococci* (MS). The results show that xylitol is versatile and effective among several delivery methods. We looked at the range of xylitol doses that produced an effective response. To effectively prevent caries, a patient needs to take xylitol with regularity. Compliance plays a major contributing factor for xylitol efficacy.

Participants ( $n = 107$ ) were block randomized in a controlled trial conducted over 28 months to confirm the effectiveness of chewing xylitol gum beginning in the third to fifth months of pregnancy for reducing mother-child transmission of MS.<sup>7</sup> The investigators were looking to see if the chewing of xylitol gum by pregnant Japanese women would reveal similar effects demonstrated by maternal xylitol gum chewing in Nordic countries. The outcome measure was MS colonization in the children. Samples were taken from two sites: the tongue dorsum and the mucosa of the mandibular and maxillary ridges using a sterile cotton swab to collect the unstimulated saliva. (See Figure 1.)

This trial confirmed that xylitol gum chewing during pregnancy is an effective early intervention period for reducing mother-child transmission of MS. The xylitol group children exhibited significantly more non-detectable, MS-negative levels (score 0) on the tooth ridges or tongue and the gingival ridge at nine, 12, and 24 months. The xylitol group children were also significantly less likely to be MS-positive than the control group children at and after nine months of age. The investigators reported that the children whose mothers did not chew xylitol gum acquired MS 8.8 months earlier than did those whose mothers did chew the gum.<sup>7</sup>

**Figure 1. Chewing Xylitol Gum During Pregnancy as *Mutans Streptococci* Colonization<sup>7</sup>**

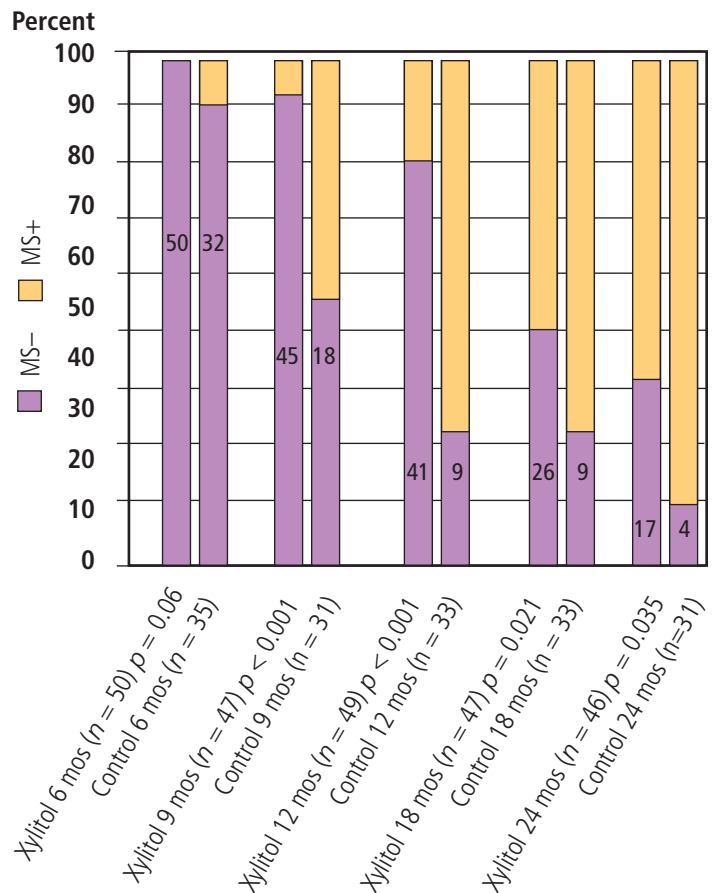


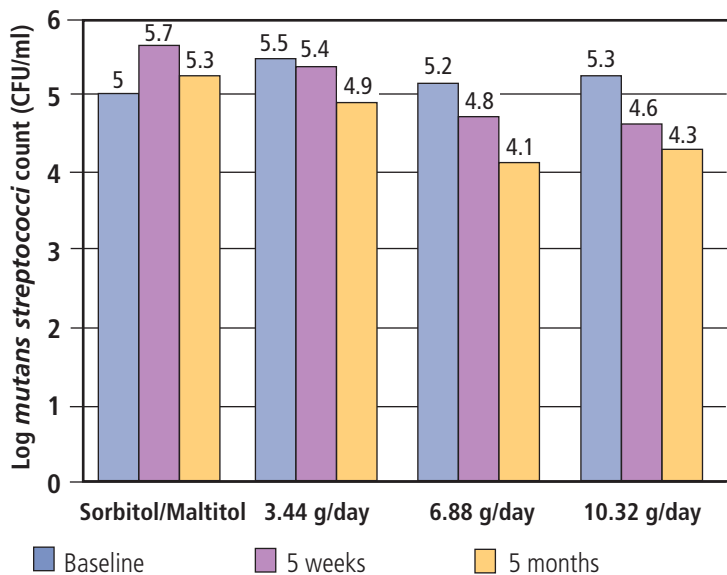
Figure 1 illustrates the results from the two combined sites to analyze the presence of *mutans streptococci* (MS) colonization. The children were dichotomized as MS positive (score 1-3 on either strip) or MS negative (score 0 on both strips) for MS colonization.

At the time, the investigators reported that the study was the first to detail the effectiveness of maternal xylitol exposure during an earlier intervention period. The results from this trial reveal that maternal exposure to xylitol chewing gum provides intervention by preventing or delaying mother-child MS transmission. From a public health viewpoint, dental practitioners might consider informing expectant mothers about the benefits of xylitol gum chewing during hygiene instruction. Similar to other studies, several limitations involving compliance are described in this study. The dose compliance limitation should be scrutinized further before recommending the xylitol chewing gum as an intervention strategy for pregnant women. Expectant mothers will need to chew xylitol gum three to five times a day, beginning in the third to fifth months of pregnancy, along with following basic prevention measures in order to gain the benefits of reducing mother-child transmission of MS reflected in this study.

### Dose Response from Xylitol Gum Chewing

A prospective controlled, double-blind clinical trial with four groups of 33 participants each ( $n = 132$ ) was conducted over six months to determine the relationship between dose and effects on *mutans streptococci* for adults chewing xylitol gum.<sup>8</sup> The participants were block randomized as follows: the control group (G1) received sorbitol/maltitol and the three active groups

**Figure 2. Mutans Streptococci in Plaque<sup>8</sup>**



**Figure 2 shows the trend of mutans streptococci levels decreasing as exposure to xylitol is increased over six months.**

received a mixture of control gum and/or xylitol gum: 3.44 g/day (G2), 6.88 g/day (G3), or 10.32 g/day (G4). The participants were instructed to chew three pellets four times per day. Plaque and unstimulated saliva samples were taken at baseline. MS levels in plaque were measured from samples taken at five weeks and in plaque and unstimulated saliva at six months. (See Figure 2.) The investigators reported that MS levels in plaque decreased as exposure to xylitol increased, and found what appeared to be a plateau effect between 6.88 g/day and 10.32 g/day.

### Xylitol Syrup Administered to Children

Children with early childhood caries are three times more likely to develop tooth decay in permanent teeth than children without childhood caries. The use of products containing xylitol has been investigated as a way to prevent caries in children. An effective xylitol vehicle that is acceptable and safe for toddlers has been elusive. In addition, the effectiveness of xylitol is dependent on a minimum daily quantity and frequency, which means that it has limited patient compliance and, thus, effectiveness.

Milgrom et al. conducted a double-blind, randomized controlled trial using a xylitol topical syrup to determine the effectiveness in children.<sup>9</sup> (See Table 1.) Xylitol oral syrup administered as little as twice daily at a total daily dose of 8 grams was found to be effective in preventing childhood caries.

Controversies noted in this study were whether or not xylitol’s effectiveness was attributed to the anticariogenic effect of xylitol itself, or whether it was a result of chewing and digestion activities of the products consumed. The researchers assert that their results, using just syrup, more accurately reflect the effects of xylitol use versus the current studies conducted with gum and lozenges that don’t take into account increased saliva flow, food removal from the oral cavity, and pH of the mouth that assists in caries reduction and prevention. Their research confirms the effectiveness of xylitol alone.

The study results also indicate that an alternative xylitol vehicle has been found for young children. Toddlers, who are one of the high-risk groups for caries development, are unable to consume typical xylitol products, such as gum and lozenges, due to safety and choking concerns. With only two applications of the syrup required per day for effectiveness, compliance will be much easier to accomplish, thereby increasing the therapeutic effect and caries prevention. Although a xylitol syrup product is not currently available at retail markets, there are several similar commercially available products, such as pudding, jam, and maple syrup, available in retail stores and online sites that provide the therapeutic 4.0 grams or more per serving outlined in the study.<sup>10</sup> Dentists or dental hygienists recommending this treatment will need to caution parents about the potential for loose stool and diarrhea; approximately 10 percent of the study’s participants experienced these adverse effects. The authors noted that a gradual increase in dosage during the treatment aided the patient’s acclimatization to xylitol and reduced the adverse gastrointestinal problems.

### The Effectiveness of Xylitol Gummy Bear Snacks

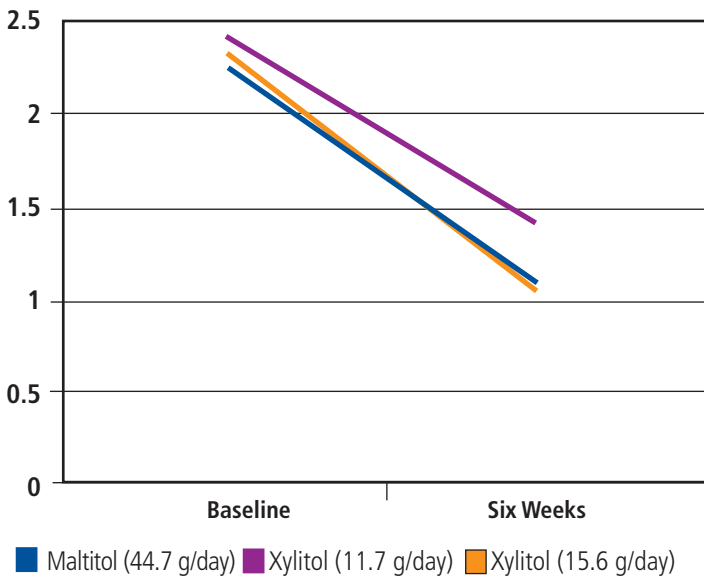
One other study looked at the habitual consumption of xylitol gummy bear snacks and its effectiveness in reducing MS.<sup>11</sup> After six weeks of providing school-age children with gummy bear snacks containing xylitol at 11.7 grams per day, the study revealed significant reduction in *Streptococcus mutans* and *Streptococcus sobrinus*, a species of gram-positive, coccoid bacteria isolated from human tooth surfaces and shown to be cariogenic in experimental animals.

Tooth decay prevention programs using xylitol chewing gum and hard candies are currently popular in Europe, Korea, Japan, Thailand, and China; however, they have not been adopted in the United States due to the fact that gum and candies present a choking hazard to children and are not considered an acceptable delivery vehicle. The results of this study, however, have identified what may be an effective alternative vehicle

**Table 1. Percentage with Tooth Decay and Number of Decayed Teeth Among 94 Children Administered Xylitol Oral Syrup<sup>12</sup>**

Group	Percentage with Decayed Teeth	Number of Decayed Teeth, Mean
Control Group	51.7	1.9
Xylitol—2X per day, 4.0 g per dose	24.2	0.6
Xylitol—3X per day, 2.67 g per dose	40.6	1.0

**Figure 3. Mean *S. Mutans/Sobrinus* Levels in Plaque at Baseline and After Six Weeks of Gummy Bear Exposure<sup>11</sup>**



for administering xylitol, one that could lead to successful oral health prevention programs for U.S. children.

The study design was a double-blind, randomized trial using three groups. The three groups were children who received either 11.7 g or 15.6 g of xylitol per day, or maltitol at 44.7 g per day. The design controlled for the frequency and the number of gummy bears consumed. A total of 154 children per group were selected for the study. The results showed that after six weeks of habitual consumption of xylitol gummy bears, the levels of *S. mutans/sobrinus* were significantly reduced compared to the baseline levels. The study also noted a plateau effect at higher xylitol dose levels. (See Figure 3.) The authors also determined that doses greater than 11.7 g per day did not result in a statistically significant reduction in *S. mutans/sobrinus* levels.

### Mouthrinses: Xylitol/Chlorhexidine Versus Xylitol or Chlorhexidine Alone

In 2008, Decker et al. investigated the effect of combining xylitol and chlorhexidine on the viability of *Streptococcus sanguis* or *S. mutans* during the early stages of biofilm development and how the combination compared to xylitol and chlorhexidine alone.<sup>12</sup> The xylitol/chlorhexidine combination showed a statistically significant antiviral effect on streptococci when compared to pure xylitol or chlorhexidine used alone. This newly discovered synergistic effect of xylitol and chlorhexidine could be used in new caries prevention programs for high-risk caries patients or for reducing MS transmission from mother to child.

The experiment design used *S. sanguis* and *S. mutans* suspended in human saliva. The suspensions were exposed to the sodium chloride, xylitol, chlorhexidine, and xylitol/chlorhexidine test solutions, and then allowed to attach to human enamel slides. The vitality of the bacteria was monitored using fluorescent DNA stains and epifluorescence microscopy. Total bacterial cell counts and the growth of suspended streptococci were also measured. The data showed that both *S. mutans* and *S. sanguis* were sensitive to the chlorhexidine and xylitol/chlorhexidine solutions, with the most significant reductions in enamel adhesion

realized by the xylitol/chlorhexidine solution. Bacterial count results showed that *S. sanguis* was most sensitive to the antiseptic effects of chlorhexidine alone, while *S. mutans* colonies were more sensitive to the xylitol/chlorhexidine solution.

### Conclusion

Xylitol has been shown to be effective in the prevention of caries when consumed in quantities as little as 8 grams per day. The range of commercially available products containing 4 grams of xylitol or higher per serving has expanded in recent years, providing greater opportunities for use in a wider population.<sup>10</sup> A recent study<sup>12</sup> has also shown that using xylitol combined with the established antibacterial agent chlorhexidine improves xylitol's antibiotic capabilities. Several studies have outlined successful caries prevention program designs using xylitol for children and toddlers,<sup>11,13</sup> populations that have the highest risk for caries and that present difficult challenges for obtaining compliance with xylitol consumption. These new xylitol products and successful caries prevention programs can provide the dental team with important tools for caries management.

Although underutilized and often overlooked, xylitol use is compatible and complementary with all current oral hygiene recommendations. Xylitol is not a panacea, but it is a convenient, pleasant, practical, effective, and essential adjunct to state-of-the-art caries prevention programs. ■

### References

1. Makinen KK, Scheinin A. Xylitol and dental caries. *Ann Rev Nutr.* 1982;2:133-150.
2. Burt B. The use of sorbitol and xylitol sweetened chewing gum in caries control. *JADA.* 2006;137(2):190-196.
3. Kontiokari T, Uhari M, Koskela M. Effect of xylitol on growth of nasopharyngeal bacteria in vitro. *Antimicrob Agents Chemother.* 1995;39(8):1820-1823.
4. Uhari M, Kontiokari I, Koskela M, et al. Xylitol chewing gum in prevention of acute otitis media. *BMJ.* 1996;313(7066):1180-1184.
5. Georgieff M, Moldawer LL, Bistran BR, et al. Xylitol, an energy source for intravenous nutrition after trauma. *J Parent Enter Nutr.* 1985;9(2):199-209.
6. Peldyak J, Makinen K. Xylitol for caries prevention. *J Dent Hygiene.* 2002;76(40):276-285.
7. Nakai Y, Shinga-Ishihara C, Kaji M, Moriya K, Murakami-Yamanaka K, Takimura M. Xylitol gum and maternal transmission of mutans streptococci. *J Dent Res* 2010;89(1):56-60.
8. Milgrom P, Ly K, Roberts M, Rothens M, Mueller G, and Yamaguchi D. Mutans streptococci dose response to xylitol chewing gum. *J Dent Res.* 2006;85(2):177-181.
9. Milgrom P, Ly KA, Tut O, Mancl L, Roberts M, Briand K, Gancio M. Xylitol pediatric topical oral syrup to prevent dental caries. *Arch Pediatr Adolesc Med.* 2009; 163(7):601-607.
10. Milgrom P, Ly KA, Rothen M. Xylitol and its vehicles for public health needs. *Adv Dent Res.* 2009;21(1):44-47.
11. Ly KA, Riedy CA, Milgrom P, Rothen M, Roberts MC, Zhou L. Xylitol gummy bear snacks: a school-based randomized clinical trial. *BMC Oral Health.* 2008;8(20):1-11.
12. Decker EM, Maier G, Axmann D, Brex M, vonOhle C. Effect of xylitol/chlorhexidine versus xylitol or chlorhexidine as single rinses on initial biofilm formation of cariogenic streptococci. *Quintessence International.* 2008;39(1):17-22.
13. Honkala E, Honkala S, Shyama M, Al-Mutawa SA. Field trial on caries prevention with xylitol candies among disabled school students. *Caries Research.* 2006;40(6):508-513.



Dr. Louise Reiss

Image courtesy of Becker Medical Library, Washington University School of Medicine

# Radioactive Fallout and the Baby Tooth Survey: “I Gave My Tooth to Science”

**CHARLES B. MILLSTEIN, DDS, MPH**

*Dr. Millstein is the historian of the Massachusetts Dental Society, as well as an endodontist with a practice in Cambridge.*

**O**n August 5, 1963, U.S. Secretary of State Dean Rusk signed the Partial Nuclear Test Ban Treaty in Moscow. Cosigners were representatives of the British and Russian governments. On September 24, 1963, the Senate ratified the document and on October 10, 1963, it became an enforceable accord.

Weapons testing or any other nuclear explosion in the atmosphere, outer space, or under water were strictly forbidden. With qualifications, underground testing remained a viable alternative. The signers all understood the probability of cumulative contamination of the environment, leading to possible genetic damage as well as leukemogenesis.<sup>1</sup>

Commanding experimental evidence that helped alert President John F. Kennedy to both initiate and negotiate this treaty centered on the concrete results of the Baby Tooth Survey that began in 1959. A small outspoken group of scientists and concerned citizens volunteered their time as members of the Greater St. Louis Citizens Committee for Nuclear Information (CNI). They were responsible for both obtaining and promulgating the necessary data that showed the varying levels of radioactive material from fallout that was absorbed into the deciduous teeth and skeletal structure of children during the stages of calcification.<sup>2</sup>

The need for the CNI became evident after the United States dropped two nuclear bombs on Japan to end World War II in 1945. Both the Soviet Union and the United States began testing larger and more destructive bombs, resulting in fallout throughout the atmosphere. Our tests were done in secret and confined to spe-

cific areas. The Atomic Energy Commission (AEC) incorrectly assumed that the fallout would remain aloft in the stratosphere as it slowly decayed.

Some of the secret reports were declassified in 1954 and independent scientists further analyzed the fallout data. Individuals such as E. B. Lewis, a geneticist from Caltech, showed that iodine-131 could cause thyroid cancer in children. Linus Pauling, also from Caltech, added carbon-14 to the list, and Erville Graham, a Canadian botanist, demonstrated that the elements were absorbed by lichens, endangering the peoples of the Arctic. These were only a few of more than 100 chemicals created by the nuclear explosions.<sup>3</sup>

Strontium-90 (Sr-90), a major radioactive isotope, follows the metabolic pathways of calcium as it is deposited in bones and teeth. Its absorption increases during children's growth periods; young people have a higher biological radiodensity than adults and accumulate this isotope more readily. Because of the difficulties of monitoring Sr-90 in the skeletal system, the deciduous teeth, which have a chemical composition similar to that of bone, were used for analysis. Later, accurate data would establish the correlation of Sr-90 uptake in bone and teeth as being nearly equivalent.

In the spring of 1957, Linus Pauling, the 1954 Nobel Prize winner in chemistry, lectured to the staff and faculty of Washington University (WU) in St. Louis, Missouri. Pauling spoke of the need to halt atmospheric testing of nuclear weapons. Later that day, in the office of physicist Edward Condon, Pauling drew up a petition that called for immediate action to address this problem by international agreement. The initial 27 signers grew to 11,000 members of the scientific community in 43 countries



as Pauling and his wife, Ava Helen Miller, worked diligently to enlist the academic society and acquire its signatures. In January 1958, Pauling presented the list to Secretary General of the United Nations Dag Hammarskjöld.<sup>4</sup>

Following several years of trying to change the Atomic Energy Commission's mission, a number of WU's science faculty, along with a tireless group of civic leaders, combined their efforts to form the CNI on April 21, 1958. The members were motivated by their deep misgivings regarding both the biological and moral implications of the weapons race.<sup>4</sup>

### Radiation Monitoring of Teeth

Dr. Alfred Schwartz, assistant professor of clinical pediatrics as well as the CNI's vice president and treasurer, had read an article in *Nature* by Dr. Herman Kalckar, a biochemist and former research fellow at WU. The article, "An International Milk Teeth Radiation Census," alerted its readers to the practicality of using the deciduous dentition as a measuring tool for radioisotope fallout. The idea of using teeth came from two dental scientists, Wallace Armstrong and Seymour Kreshover. The former was a biochemist at the University of Minnesota and an authority on calcium metabolism of teeth and bones, as well as the effect of fluoride on the dentition. The latter, a dentist and pathologist, was scientific director of the National Institute of Dental Research (NIDR). Both noted that radiation monitoring of deciduous teeth would reflect the situation, as it was about seven years earlier when the calcification process took place within the first year of life.<sup>5</sup>

With Dr. Schwartz's urging, the CNI established itself as the first group anywhere to initiate a large collection of milk teeth to be analyzed for radioactivity. The well-planned study had the endorsement of the dental deans of St. Louis University and WU, along with a skilled public relations expert. With the approval of organized dentistry, a Scientific Advisory Group of dentists and scientists came into being. The WU School of Dentistry (the school changed its name to the WU School of Dental Medicine in 1974) further aligned itself by forming a research team that applied for a grant from the NIDR of the U.S. Public Health Service and received an initial five-year grant for \$197,454 that included building a laboratory.<sup>6</sup>

Botanist Barry Commoner was an early voice heard at WU in favor of stopping nuclear testing. As a founding member of the CNI, he urged the group to name an internist who was also with the local health department to take charge of the survey. Dr. Louise Reiss, who served as vice president and director of the project from 1959 to 1961, published her preliminary findings of Sr-90 uptake in deciduous teeth in the November 24, 1961, issue of *Science*.<sup>7</sup>

From 1959 to 1961, the CNI harvested 61,000 deciduous teeth for chemical analysis. The program ended in 1971 with a collection of more than 300,000 teeth. Dr. Reiss and her volunteer associates had extraordinary success in getting local schools, libraries, dental societies, and the city dental clinics to help in their efforts. The teeth were classified by Dr. Florence Rich, a pedodontist. Then they were chemically analyzed at the WU School of Dentistry by Dr. Harold Rosenthal, a biochemist at the medical and dental school; Dr. John E. Gilster, a pedodontist; and Dr. John T. Bird, a professor of dental medicine. The Sr-90 analyses were done at a private firm in New Jersey. Dr. Reiss and the professional group involved ensured that the scientific protocol was strictly observed.

In her *Science* article, Dr. Reiss proved that analysis of deciduous teeth provided a practical method of monitoring Sr-90 uptake anywhere in the world. In addition, she found that the uptake by both teeth and bones, developing in the same environment, was similar enough to use the dental data for further studies. The study noted comparable concentrations of Sr-90 in teeth of bottle- and breast-fed infants.<sup>7</sup>

### Conclusion

WU scientists found that radioisotope levels in baby teeth of children born between 1945 and 1965 had risen a hundredfold and that the levels of Sr-90 rose and fell in correlation with atomic bomb testing. During this period of the Cold War, the United States and the Union of Soviet Socialist Republics (USSR) detonated more than 400 nuclear weapons. Also, a Public Health Service survey showed an alarming rise in the percentage of live underweight births and childhood cancers.<sup>6</sup>

Because the AEC's mission was narrow and served its self-justifying purpose, it took independent scientists to understand their own obligation to society. The CNI brought concerned scientists and civic-minded individuals together and developed irrefutable information for presentation to our elected officials. In August 1963, the Test Ban Treaty was signed. Before it was ratified, Dr. Reiss's husband, Dr. Eric Reiss of Washington University Medical School, who specialized in calcium and parathyroid metabolism, presented the results of her study to a Senate subcommittee. The Senate ratified the treaty on September 24, 1963.<sup>8</sup>

Even though there were many Cold War adherents in our governing bodies, they also began to shift their bias because of the many letters they received from constituents who sensed the dangers of radioactive fallout. To these citizens, the health of the next generation was of prime importance. With Dr. Eric Reiss's presentation, the CNI had successfully made its case. When the treaty went into force on October 10, 1963, Linus Pauling was notified that he was to be awarded the Nobel Peace Prize.<sup>9</sup>

In 1972, Dr. Eric Reiss joined the faculty of the University of Miami School of Medicine. He died in 1988 at the age of 63 and, several years later, the Eric Reiss Faculty Development and Learning Resource Center was dedicated in his honor. He is remembered for his legacy as a role model in academic medicine and for his intellectual curiosity that he so consistently stimulated in others.<sup>10</sup>

Dr. Louise Reiss passed away on January 10, 2011, at the age of 90. In her later years, she studied the creative process in humans, which led to a published text in 2005. She remained proud of the Baby Tooth Survey that had achieved its

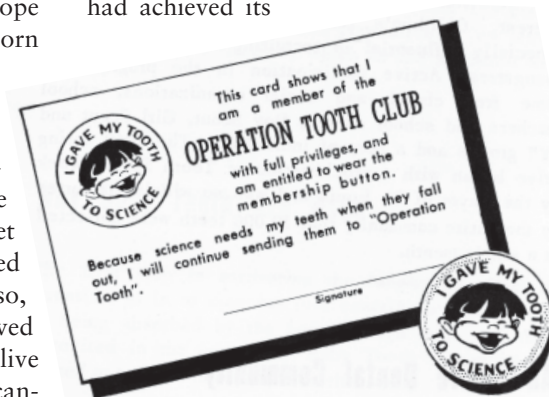

Image courtesy of Rosenthal Papers, WUSTL Archives

# RDH TEMPS

NO HASSLES. NO WORRIES. THE RESOURCE FOR DENTAL HIRING.

[www.rdhtemps.net](http://www.rdhtemps.net)  
1-800-462-TEMP OR 1-888-RDH-TEMP  
Serving CT, MA, NH and RI



## Flexibility.

- Temporary and permanent staffing exclusively for the dental industry.
- Dentists, Dental Hygienists, Dental Assistants and Administrative Staff.
- Centrally owned and operated since 1979 with local specialists.
- Flexible temporary rates; proportional rebates should a permanent placement fail to last.
- All dental auxiliary and administrative temps are our employees.
- Personnel are interviewed in person and are pre-screened.
- Extensive live phone coverage by a large team of staffing experts.
- RDH Temps carries professional liability (malpractice) insurance on all Dental Hygienists & Assistants.

**New!**  
Flexible rates!  
Proportional  
management fees!  
No daily overtime!  
70% of customers will  
save an average of  
\$19 per day!

aims through science rather than politics. Writing to a colleague, she noted, "I continue to be moved by the knowledge that a group of organized people can effectively pressure government if they come up with data instead of rhetoric."<sup>8</sup>

### Author's Note

The Washington University School of Dental Medicine closed in 1991 after 125 years of service. In 2001, the WU Medical School recovered 85,000 teeth that were not used in the survey. Each donor's tooth was in a small envelope and every donor had received a badge stating, "I gave my tooth to science." The Radiation and Public Health Project, an independent research group, accepted the collection. In a new study, it addressed the issue of cancer risk from fallout rather than just assessing the increased Sr-90 levels. In December 2010, the group published its results in the *International Journal of Health Issues*. Using a small sample, preliminary findings suggest that donors of the original project who died of cancer by age 50 had more than twice the average Sr-90 levels than donors who were healthy at the same age.<sup>8</sup> ■

### References

1. U.S. National Archives & Records Administration. Transcript of Test Ban Treaty. 1963. Available from: <http://www.ourdocuments.gov/doc.php?doc=95>
2. Washington University School of Dental Medicine. St. Louis Baby Tooth Survey, 1959-1970. Bernard Becker Medical Library. Available from: <http://beckerexhibits.wustl.edu/dental/articles/babytooth.html>
3. Hall A. Interview with Barry Commoner. *Scientific Am.* 1997 Jun 23. Available from: <http://www.scientificamerican.com/article.cfm?id=interview-with-barry-comm>
4. Wyant WK. 50,000 baby teeth. *The Nation.* 1959 Jun 13:535-537.
5. Kalckar HM. An international milk teeth radiation census. *Nature.* 1958;182(4631):283-428.
6. Washington University School of Dental Medicine. St. Louis Baby Tooth Survey, 1959-1960. Bernard Becker Medical Library; p. 2.
7. Reiss LZ. Strontium-90 absorption by deciduous teeth. *Science.* 1961;134(3491):1669-1673.
8. Hevesi D. Dr. Louise Reiss, who helped ban atomic testing, dies at 90. *New York Times.* 2011 Jan 10. Available from: [http://www.nytimes.com/2011/01/10/science/10reiss.html?\\_r=1](http://www.nytimes.com/2011/01/10/science/10reiss.html?_r=1)
9. National Institutes of Health. The Linus Pauling papers: two Nobel Prizes. Bethesda (MD): U.S. National Library of Medicine.
10. Karl M. Obituary of Dr. Eric Reiss. St. Louis (MO): Washington University School of Medicine.

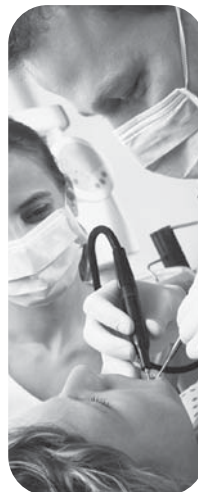## REWARDING OPPORTUNITIES

for Dentists & Specialists in Massachusetts



### • NATIONAL RESOURCES

in a "Hometown" Environment



### • COMPREHENSIVE BENEFITS

including Health, Liability, Retirement Savings, plus more.

### • RELOCATION ASSISTANCE AVAILABLE

### • MORE THAN 150 CENTERS

in Connecticut, Florida, Georgia, Massachusetts, Michigan, Ohio and Virginia

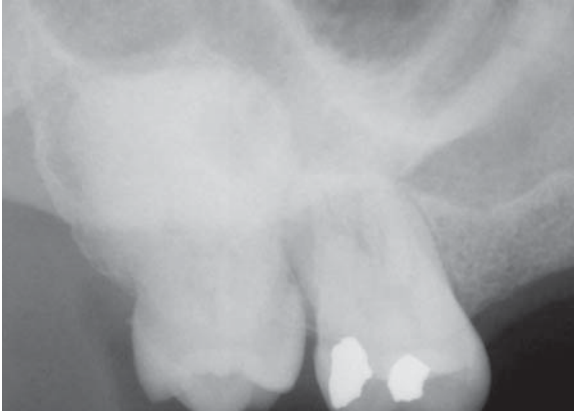### • APPLY ONLINE AT:

[greatexpressions.com/careers](http://greatexpressions.com/careers)

• CONTACT: Amanda Barrette  
Recruiting Manager  
248-203-1108

# A Clinico-Pathologic Correlation

## Complex Odontoma in Posterior Maxilla

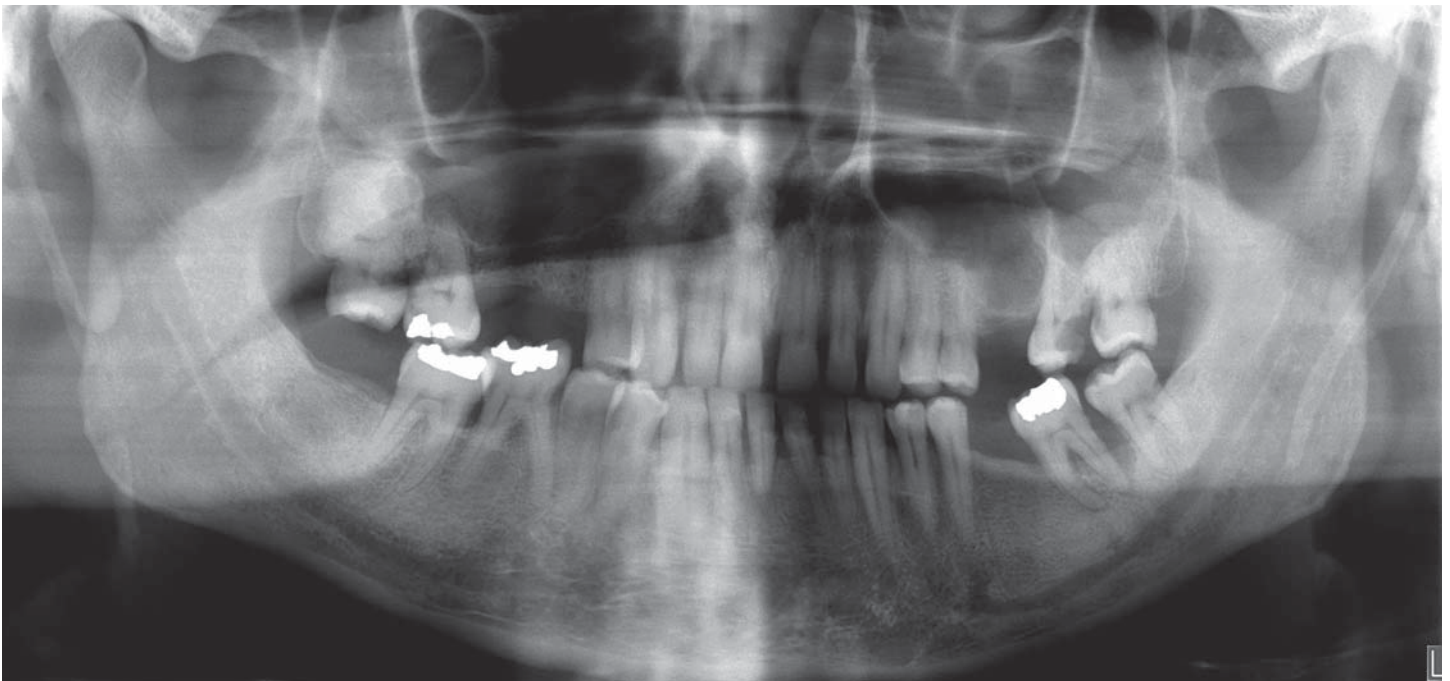


**Figure 1.** Periapical X-ray showing a large radiopaque lesion associated with the apex of tooth #1.

**GHASSAN DARWISH, BDS**

**DANIEL OREADI, DMD**

*Dr. Darwish is an intern and Dr. Oreadi is an assistant professor in the department of oral and maxillofacial surgery at Tufts University School of Dental Medicine.*



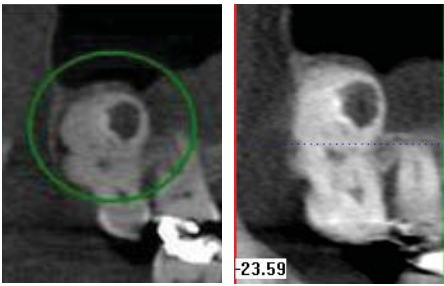
**Figure 2.** Panoramic X-ray showing multiple nonrestorable teeth and the lesion associated with tooth #1.

### Case Presentation

**A** 62-year-old healthy male with no known drug allergies and who takes no medications was referred to the oral and maxillofacial surgery department at Tufts University School of Dental Medicine to evaluate a lesion associated with the roots of the upper-right third molar (tooth #1).

The patient had no reports of pain, inflammation, or previous infection, and a head-and-neck examination revealed no abnormalities, swelling, or tenderness. Intraoral examination showed normal soft and hard tissues of the vestibule, palate, buccal mucosa, floor of the mouth, and tongue. In addition, multiple nonrestorable teeth were present.

Periapical and panoramic radiographs showed a radiopaque mass surrounding the roots of the upper-right third molar. (See Figures 1 and 2.) Axial and multiplanar reconstructed cone-beam computed tomography (CBCT) showed a well-defined,



Figures 3a–3b. CBCT images showing the radiolucency within the radiopaque lesion.

mixed-density lesion associated with the apex of the upper-right third molar with a large area of central radiolucency within the radiopacity. (See Figures 3a–3b.)

### Differential Diagnosis

Complex odontoma  
Compound odontoma  
Cementoma  
Cementifying fibroma  
Cementoblastoma  
Ossifying fibroma

### Diagnosis

Complex odontoma

### Discussion

Odontomas are the most common benign odontogenic tumors of mixed epithelial and mesenchymal origin. They are considered to be developmental anomalies (hamartomas) rather than true neoplasms.<sup>1</sup> The World Health Organization (WHO) defines complex odontoma as malformation in which all dental tissues are present (enamel, dentin, cementum, and pulp), but arranged in a more or less disorderly pattern.<sup>2</sup> These lesions are characterized by slow growth and non-aggressive behavior, and with excellent prognosis.<sup>3</sup> Asymptomatic lesions are a common incidental finding when radiographic evaluation is performed and should be carefully analyzed.<sup>4</sup>

Odontomas are the most prevalent benign mixed tumors in the jaws. They are of unknown etiology and are usually discovered incidentally during the second and third decades of life.<sup>1</sup> Male patients are more commonly affected than females (1.5:1). Most complex odontomas are localized in the posterior region of the mandible. Radiographic appearance of complex odontomas usually occurs as a radiopaque mass surrounded with a thin radiolucent rim.<sup>1,3</sup> In this patient, a CBCT

was necessary to determine the extent of the lesion because of the two-dimensional limitation of the panoramic film.

CBCT revealed a well-defined, corticated mixed-density lesion associated with the apex of the upper-right third molar, measuring approximately 17 mm × 14 mm × 10 mm. There was a large area of central radiolucency within the radiopacity. The borders of the lesion appeared continuous with the cementum with possible root resorption. There was superior displacement of the inferior border of the right maxillary sinus.

The patient underwent extraction of the upper-right third molar and biopsy of the lesion under IV sedation. Two carpules of xylocaine 2% with 1:100,000 Epi were used, and a full-thickness mucoperiosteal flap was reflected with releasing incision. The lesion, which came attached to the tooth roots (see Figures 4 and 5), was removed using an upper universal forceps. The extraction site was inspected, all granulation tissue was removed, and bone filling was performed. The treatment area was irrigated with normal saline, and 3-0 chromic gut sutures were placed. Hemostasis was achieved. The patient tolerated the procedure well.

After one week, the patient presented to the clinic for follow-up. At this time, he noted no complaint and denied having any discharge from the nose. Clinical examination revealed no inflammation, discharge, or evidence of oroantral communication.

### Conclusion

Odontomas are considered mixed odontogenic tumors,<sup>1</sup> although odontomas are typically less aggressive and asymptomatic. But careful histologic and radiographic examinations of these lesions are necessary because the lesions may resemble a much more aggressive neoplasm.<sup>5</sup> Also, removal of the lesion and enveloping soft tissue is necessary to prevent the possibility of cystic formation.<sup>4</sup> Complex odontomas are diagnosed less frequently than compound odontomas, due to the fact that some compound odontomas are not submitted for microscopic examination because the clinician is comfortable with the diagnosis clinically and radiographically.<sup>1</sup> ■

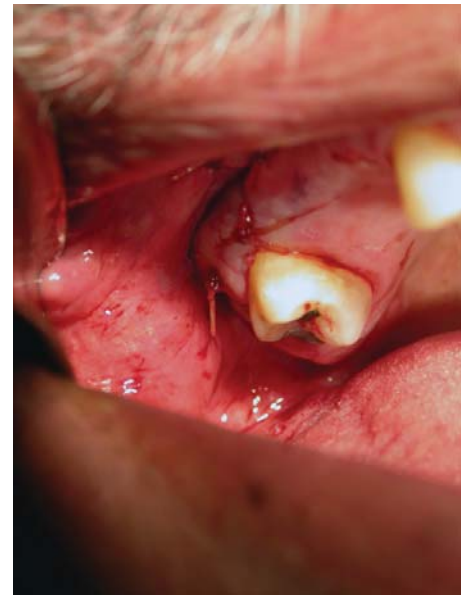


Figure 4. Intraoral image showing the surgical site postoperative removal of the tooth and the lesion.

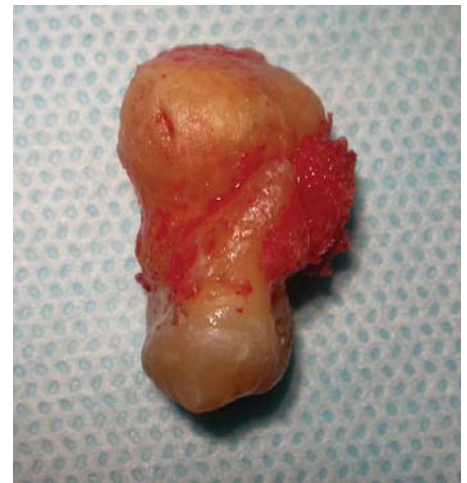

Figure 5. Clinical image showing the lesion attached to the tooth roots.

### References

1. Neville B, Damm D, Allen C, Bouquot J. Oral & Maxillofacial Pathology. 3rd ed. St. Louis (MO): Saunders Elsevier; 2009. p. 724-726.
2. Kramer I, Pindborg J, Shear M. Histological typing of odontogenic tumours. New York, (NY): Springer-Verlag; 1992.
3. Vengal M, Arora H, Ghosh S, Pal KM. Large erupting complex odontoma: a case report. J Can Dent Assoc. 2007;73(2):169-173.
4. Phillipsen H, Reichardt P, Praetorius F. Mixed odontogenic tumours and odontomas. Considerations on interrelationship. Review of literature and presentation of 134 new cases of odontomas. Oral Oncol. 1977;33(2):86-99.
5. Mupparapu M, Singer SR, Rinaggio J. Complex odontoma of unusual size involving the maxillary sinus: report of a case and review of CT and histopathologic features. Quintessence Int. 2004;35(8):641-645.



**VIKKI NOONAN, DMD, DMSc**  
**SADRU KABANI, DMD, MS**  
**KARIM ALIBHAI, DMD**

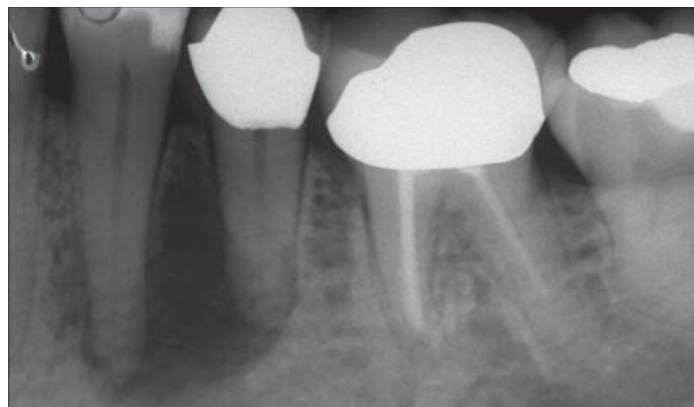
*Drs. Noonan and Kabani are oral and maxillofacial pathologists at the Center for Oral Pathology at Strata Pathology Services in Cambridge, MA, and Dr. Alibhai is a diplomate of the American Board of Endodontics and maintains private practices in Bellevue and Renton, WA.*

## LANGERHANS CELL HISTIOCYTOSIS (EOSINOPHILIC GRANULOMA)

**L**ANGERHANS CELL HISTIOCYTOSIS (eosinophilic granuloma) is a relatively uncommon phenomenon that affects the jaws in approximately 8 to 20 percent of all cases of the condition.<sup>1,2</sup> Although the pathogenesis is not completely understood, immunologic dysregulation has been postulated to be the underlying cause of this clonal proliferation of cells that normally function as antigen-presenting cells in the skin, mucosa, lymph nodes, and bone marrow.<sup>3-7</sup> Langerhans cell histiocytosis may present in patients over a wide age range, with 50 percent of cases arising in patients under the age of 15.<sup>4</sup>

Jaw lesions classically present as a “punched-out” corticated to ill-defined radiolucency of the posterior mandible, and when associated with root apices, the pattern of bone loss may resemble inflammatory periapical pathology (periapical granuloma or radicular cyst) or may give teeth the appearance of “floating-in-air,” mimicking severe periodontitis. Common clinical symptoms of Langerhans cell histiocytosis include pain, alveolar bone loss, loosening of teeth and gingival recession, poorly healing extraction socket, or pathologic fracture.

As the clinical and radiographic presentation of Langerhans cell histiocytosis is somewhat varied and may mimic a wide range of lesions—including odontogenic cysts, tumors, and malignancy, among others—a biopsy is requisite with submission of lesional tissue for histopathologic evaluation. Following



**Periapical radiograph showing marked bone loss mimicking a periapical inflammatory condition. (Image courtesy of Dr. Karim Alibhai.)**

diagnosis, referral to a patient’s physician is indicated for systemic evaluation with subsequent management dependent upon the extent of involvement, which may include surgical excision with or without chemotherapy and radiation.<sup>2,4,8</sup> ■

### References

1. Egeler RM, Nesbit ME. Langerhans cell histiocytosis and other disorders of monocyte-histiocyte lineage. *Crit Rev Oncol Hematol.* 1995;18(1):9-35.
2. Howarth DM, Gilchrist GS, Mullan BP, Wiseman GA, Edmonson JH, Schomberg PJ. Langerhans cell histiocytosis: diagnosis, natural history, management, and outcome. *Cancer.* 1999;85(10):2278-2290.
3. Egeler RM, Favara BE, van Meurs M, Laman JD, Claassen E. Differential in situ cytokine profiles of Langerhans-like cells and T cells in Langerhans cell histiocytosis: abundant expression of cytokines relevant to disease and treatment. *Blood.* 1999;94(12):4195-4201.
4. Hicks J, Flaitz CM. Langerhans cell histiocytosis: current insights in a molecular age with emphasis on clinical oral and maxillofacial pathology practice. *Oral Surg Oral Med Oral Pathol Oral Radiol Endod.* 2005;100(2 Suppl):S42-S66.
5. Willman CL, Busque L, Griffith BB, Favara BE, McClain KL, Duncan MH, Gilliland DG. Langerhans-cell histiocytosis (histiocytosis X)—a clonal proliferative disease. *NEJM.* 1994;331(3):154-160.
6. Willman CL, McClain KL. An update on clonality, cytokines, and viral etiology in Langerhans cell histiocytosis. *Hematol Oncol Clin North Am.* 1998;12(2):407-416.
7. Yu RC, Chu C, Buluwela L, Chu AC. Clonal proliferation of Langerhans cells in Langerhans cell histiocytosis. *Lancet.* 1994;343(8900):767-768.
8. Abrahão AC, Cabral MG, Noce Dos Santos CW, Janini ME, Pulcheri WA. Polyostotic eosinophilic granuloma of the jaws treated by chemotherapy. A case report. *Minerva Stomatol.* 2007;56(7-8):405-409.



Las Vegas

American Dental Association  
**ANNUAL SESSION**  
 OCTOBER 10 - 13, 2011

### ADA 152nd Annual Session

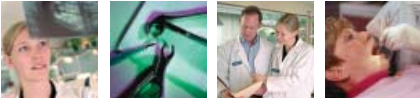Don’t miss the American Dental Association’s 152nd Annual Session and World Marketplace Exhibition, to be held at the Mandalay Bay Convention Center in Las Vegas, October 10–13, 2011.

The ADA Annual Session brings together leaders in dental practice, research, academia, and industry to present more than 250 relevant and topical continuing education courses over four days. The World Marketplace Exhibition will feature more than 500

leading suppliers of dental products and services.

Former U.S. Secretary of State Condoleezza Rice, PhD, will be featured as the 2011 Distinguished Speaker as part of the Opening General Session on Monday morning, October 10.

Registration is only \$75 for ADA member dentists. Visit [www.ada.org/session](http://www.ada.org/session) for more information, including travel and housing discounts.

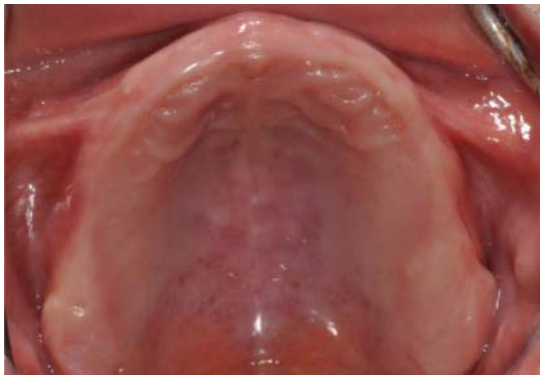

## CLINICAL CASE STUDY

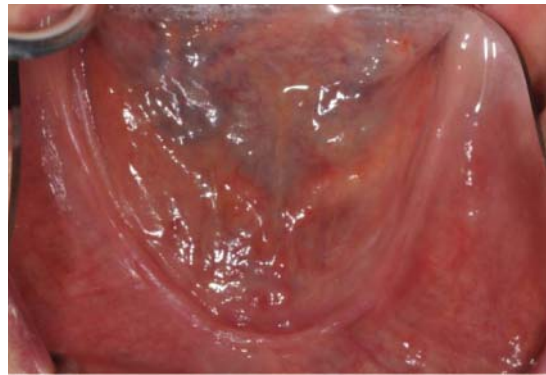
**JOOHYUNG KIM, DDS**  
**JEONG SOOK LEE, DMD**  
**JOHN CHANG, DMD, MMSc**  
**PHILIP MILLSTEIN, DMD, MS**  
**ROBERT F. WRIGHT, DDS**

*Dr. Kim and Dr. Lee are third-year residents in advanced graduate prosthodontics and MMSc candidates in oral biology, and Drs. Chang, Millstein, and Wright are faculty members in the department of restorative dentistry and biomaterials sciences, division of graduate prosthodontics, at the Harvard School of Dental Medicine.*

# A METHOD FOR ADAPTING EXISTING REMOVABLE COMPLETE DENTURES TO IMMEDIATE IMPLANTS



**Figure 1. Edentulous maxilla**



**Figure 2. Edentulous mandible**

**T**HE ALL-ON-4 TREATMENT CONCEPT WAS DEVELOPED BY NOBEL Biocare to provide edentulous patients with an effective restoration using only four implants to support an immediately loaded full-arch prosthesis.<sup>1</sup>

By tilting the two posterior implants, longer implants can be used with minimum bone volume, thereby increasing bone-to-implant contact and reducing the need for vertical bone augmentation. It also offers improved support for the prosthesis by reducing cantilevers.

### Clinical Report

The patient, a 70-year-old woman, presented to the Harvard School of Dental Medicine at the Graduate Prosthodontic Clinic for consultation, with her chief complaint being that she couldn't wear her lower denture because it was too loose. (See Figures 1 and 2.)

### Clinical Procedures

A radiographic stent was fabricated using the patient's existing denture. (See Figure 3.) Using a dual computed tomography scan, the treatment was virtually planned using NobelProcera computer-aided design and computer-aided manufacture (CAD/

CAM) software. (See Figure 4.) Virtual planning allowed for the fabrication of a surgical stent, which was used to make a master cast. (See Figure 5.)

An immediate fixed complete denture prosthesis reinforced with a metal frame on the lingual surface was fabricated utilizing the patient's existing removable denture. (See Figure 6.) Guided surgery was performed using the surgical stent to allow for the properly planned implant positioning to enhance the prosthodontic result.<sup>2</sup> (See Figures 7 and 8.) Temporary abutments were incorporated into the preexisting prosthesis. (See Figure 9.) The retromolar pads on the denture were removed and the prosthesis was immediately loaded. (See Figure 10.)

The occlusion was checked using a polydimethylsiloxane impression material and transilluminated.<sup>3,4</sup> Colored markings represent occlusal and near-occlusal contact, and white areas represent occlusal contacts. (See Figures 11 and 12.)

### Conclusion

By utilizing this technology, we were able to precisely locate the mental foramina and to tilt the posterior implants. A stable occlusion was imperative to secure the implants in function. ■

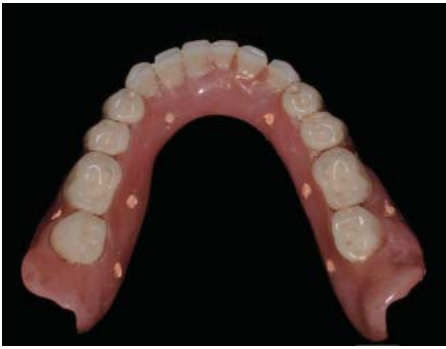

Figure 3. Radiographic stent

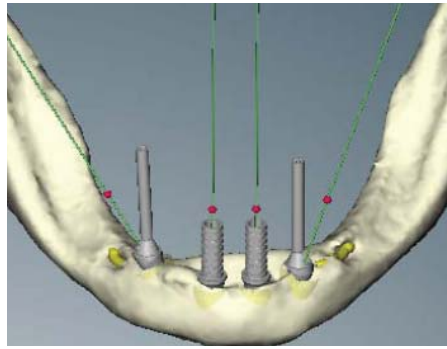


Figure 4. CAD/CAM treatment planning




Figure 5. Surgical stent

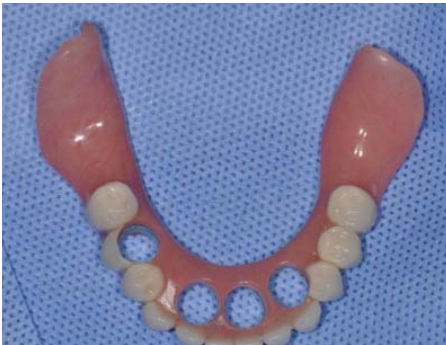

Figure 6. Denture prosthesis

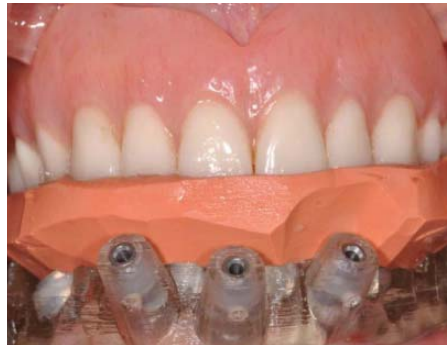

Figure 7. Surgical stent in place

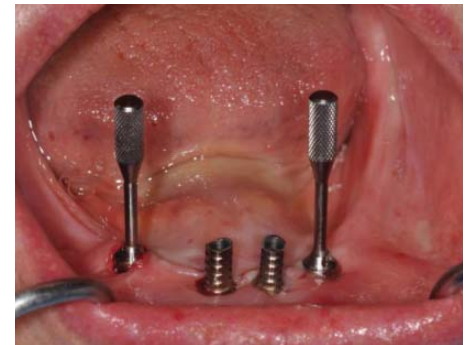

Figure 8. Implants placed

## References

1. Maló P, Rangert B, Nobre M. "All-on-Four" immediate function concept with Brånemark System implants for completely edentulous mandibles: a retrospective clinical study. *Clin Implant Dent Relat Res.* 2003;5(Suppl 1):2-9.
2. Bellini CM, Romeo D, Galbusera F, Taschieri S, Raimondi MT, Zampelis A, Francetti L. Comparison of tilted versus nontilted implant-supported prosthetic designs for the restoration of the edentulous mandible: a biomechanical study. *Int J Oral Maxillofac Implants.* 2009;24(3):511-517.
3. Hahn SM, Millstein PL, Kinnunen TH, Wright RF. The effect of impression volume and double-arch trays on the registration of maximum intercuspation. *J Prosthet Dent.* 2009;102(6):362-367.
4. Millstein PL. A method to determine occlusal contact and noncontact areas: preliminary report. *J Prosthet Dent* 1984;52(1):106-1.

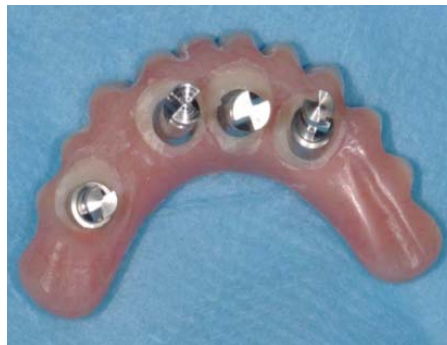

Figure 9. Temporary abutments

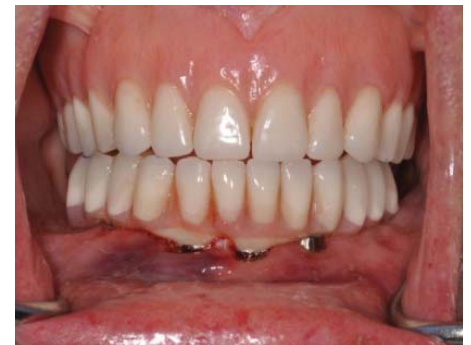

Figure 10. Adapted complete denture

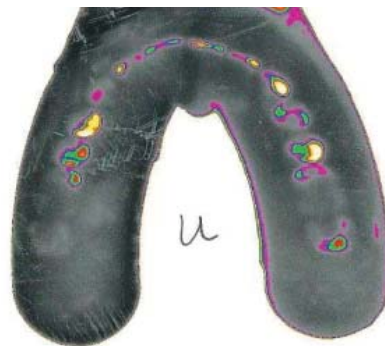


Figure 11. Centric occlusion

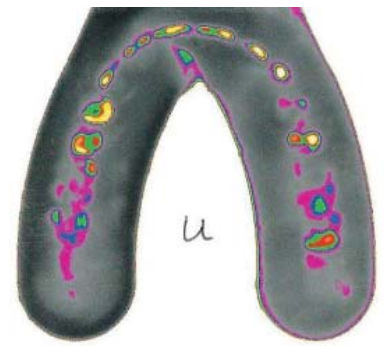

Figure 12. Protrusive

## Give Us Your Feedback on This Clinical Case Study

A Clinical Case Study is a written and visual assessment of a clinical case where the author presents before-and-after radiographs and/or photographs as a means to discuss the diagnosis, treatment plan, and actual treatment of a particular situation. The purpose of this study is to encourage JOURNAL readers to contribute a clinical response to the cases presented.

Please address your correspondence to Clinical Case Study, JOURNAL OF THE MASSACHUSETTS DENTAL SOCIETY, Two Willow Street, Suite 200, Southborough, MA 01745, or email [mcarman@massdental.org](mailto:mcarman@massdental.org). Include your name, address, and phone number or email address so that we may contact you for follow-up. Responses may be published in a future JOURNAL.



## BOOK REVIEWS

### TODD BELFBECKER, DMD


*Dr. Belfecker is a general dentist practicing in Revere.*

### Fundamentals of Color—2nd Edition Shade Matching and Communication in Esthetic Dentistry

#### STEPHEN J. CHU, DMD

*Quintessence Publishing*

This text provides a comprehensive look at shade and color, and it proves that a topic that seems simple—namely, shade selection—is actually quite complex. The book outlines how a practitioner can better his or her shade-matching technique, and it does so in a truly reader-friendly way. Written by dentists and dental technicians, the text is a good resource.



The authors write, “This book explains the basic science and art of color to help the reader better understand the mechanics involved in the shade-matching process. Moreover, it details the myriad clinical elements that can affect the perception of color.” This sums up the text in a nutshell. However, this quotation does not convey how nice a book *Fundamentals of Color* is to browse through. Nearly every page has at least several vibrant photos and/or illustrations that supplement the text well. The book was written by people who clearly appreciate esthetics, as evidenced by the high quality and clarity of the photos and diagrams.

The text is well written and educational without being overwhelming; it is highly readable. Topics of discussion include color theory; elements that may affect color and make it difficult to match shade; conventional shade matching (this includes shade tabs); and technology-based shade matching. Additionally, the authors include 12 case studies that integrate the previous chapters.

This book is in-depth, yet accessible. By outlining a wide range of factors that affect color and its perception, and also by demonstrating various techniques to choose the best shades in dental cases, the authors have written an interesting and useful textbook. I would recommend this book not only to practitioners who want advice on how to best choose shades, but also to those who are interested in the idea of color in general. The text can be an effective tool to help dentists improve their patients’ smiles.

### Oral & Maxillofacial Pathology—2nd Edition

#### BRAD NEVILLE, DOUGLAS D. DAMM,

#### CARL M. ALLEN, JERRY BOUQUOT


*W.B. Saunders*

It may seem curious that the JOURNAL is reviewing a book that was published in 2001. But as far as I’m concerned, this text

is the gold standard in oral pathology textbooks. We used it in dental school and I still refer to it often, whether for a refresher, for edification or clarification with regard to my own patients, for research, or simply for educational entertainment.

The book is well organized and easy to navigate. Each chapter is divided into distinct sections and subsections, with multiple examples of different lesions, defects, and abnormalities. Full-color photos for practically every topic are useful for comparison to real-life cases or for general knowledge. I often open the book to a random page to relearn clinical features, treatment, and prognosis of pathologies I may never see in person. The text itself is highly readable with clear and concise descriptions of each topic.

This is a must-have for any dental library.



### Treatment of Endodontic Infections

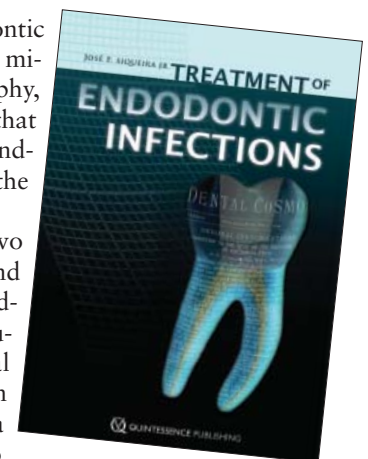
#### JOSÉ F. SIQUEIRA, JR., DDS, MSc, PhD

*Quintessence Publishing*

What distinguishes this endodontic text from others is its focus on microbiology. The text’s philosophy, as presented in the preface, is that the better the microbiology of endodontic cases is understood, the better the treatment can be.

The text is divided into two sections: “The Infection” and “The Treatment.” The first addresses microbiology and immunology as they relate to apical lesions. The intent of this section is to provide the reader with a solid background in order to understand the second section. “The Treatment” focuses on treatment of different types of endodontic infections, and the text builds upon knowledge gained from the first section. In other words, each section is unique yet interconnected with the other.

In the preface, the author states that “this is a book that attempts to narrow the gap between research and clinical practice.” It succeeds in its goal. The author writes that he created this book for students, researchers, professors, and clinicians alike. The text is technical while also being readable. Various aspects of endodontics are reviewed and taught in great detail. Effective photos and diagrams serve to enhance the text while also standing on their own in many instances. All four groups of readers that the author mentioned can use this text to enhance their knowledge and also to broaden their perspectives of endodontics. ■







## ART OF DENTISTRY

**ROY A. SCHONBRUN, DDS**

*Dr. Schonbrun practices oral and maxillofacial surgery with Connecticut Valley Oral Surgery Associates in western Massachusetts.*

### THE KISSING DISEASE

A PIECE IN *THE NEW YORK TIMES* SEVERAL MONTHS AGO—PART of a column appearing periodically about health issues—entitled “Really?” makes the specious claim that cavities are contagious. I checked twice to make sure I wasn’t reading the *National Enquirer*, but it was indeed the Science Times section of *The New York Times*. Uncharacteristically, the statement was bolstered by as much scientific evidence as one might expect from Ripley’s, and with the same dramatic effect. The culprit, not unexpectedly, is *Strep mutans*, but little did I realize that, according to the reporter, it might well be a weapon of mass destruction.

The fact that *S. mutans* is associated with dental caries is hardly news. There is abundant evidence of the role *S. mutans* plays in sucrose-dependent biofilm formation and potent acidogenesis. *S. mutans* was first isolated in 1924 and was originally associated with physiological decay, but not tooth decay. In fact, it has been postulated by some researchers (*Microbiological Reviews*, 1986) that *S. mutans* is an opportunistic organism in the tooth decay scheme of things, remaining dormant until tissue deterioration is in progress and then becoming a prevalent organism. The prevailing opinion, however, seems to strongly implicate *S. mutans* in a lead role.

That we all don’t have rampant caries is because we are endowed by our creator with certain inalienable enzymes in the saliva that deliver us from evil and protect us from being run amok by bad bugs.

While sucrose is the manna for *S. mutans* to defile, other foods help provide an anticariogenic benefit. Plant polyphenols (flavonoids) found in cocoa, coffee, tea, and citrus fruits have an antibacterial action, reducing the biofilm and acid production of *S. mutans*. Research is ongoing in Sweden to develop enzyme inhibitors to prevent destructive biofilm formation. A study published in the July 2007 *Journal of Dental Research* found that *S. mutans* subjected to oxidative stress (peroxide, peridex) appears to have a diminished growth rate.

It seems that there are a number of different approaches

under investigation to disarm the *S. mutans* threat, including the development of an antibiotic—streptozotocin, which selectively kills *S. mutans*—that was originally investigated at Boston University. This may be very helpful for individuals with a

high caries index who have certain strains of *S. mutans* that have become resistant to the usual endogenous defenses. However, the *sine qua non* of caries prevention remains diet and oral hygiene, which are directed at limiting the build-up of plaque and reducing the exposure time of teeth to it, and thus reducing destructive acidification.

In the *Times* article, the reporter comes to the stunning conclusion that cavities are contagious through the direct trans-

mission of *S. mutans* from one person to another. But leave it to the professionals to also make similar confounding assertions. For instance, a dental group in Alexandria, VA, published a newsletter for its patients with an article that stated that tooth decay is a communicable disease, and it is passed from one person to another. The September 2007 issue of the *Bradlee Dental Care Newsletter* makes the following claim: “If you are not getting regular dental care with six-month checkups at a minimum, you are infecting your children every time you kiss them, or share utensils, even talking closely to a child.” Pretty scary. But good for business, I guess.

Similarly, our intrepid *Times* reporter substantiates her conclusion about the cavity contagion by offering the opinion of a Chicago dentist, who suggests that cavities can be “catching” based on the observation of couples in her practice who were caries-free before dating and who now have cavities and gingivitis. One might say that these arguments are “cavity-ridden,” as well. It represents a reductionist view of complex physiological and biological processes, which is misleading in its abstraction (*reductio ad absurdum*) and can be considered pernicious in its manipulation.

I am afraid there is not much to chew on here. Anyway, what’s the antidote—a peck on the cheek? Probably get acne.

Really? ■

